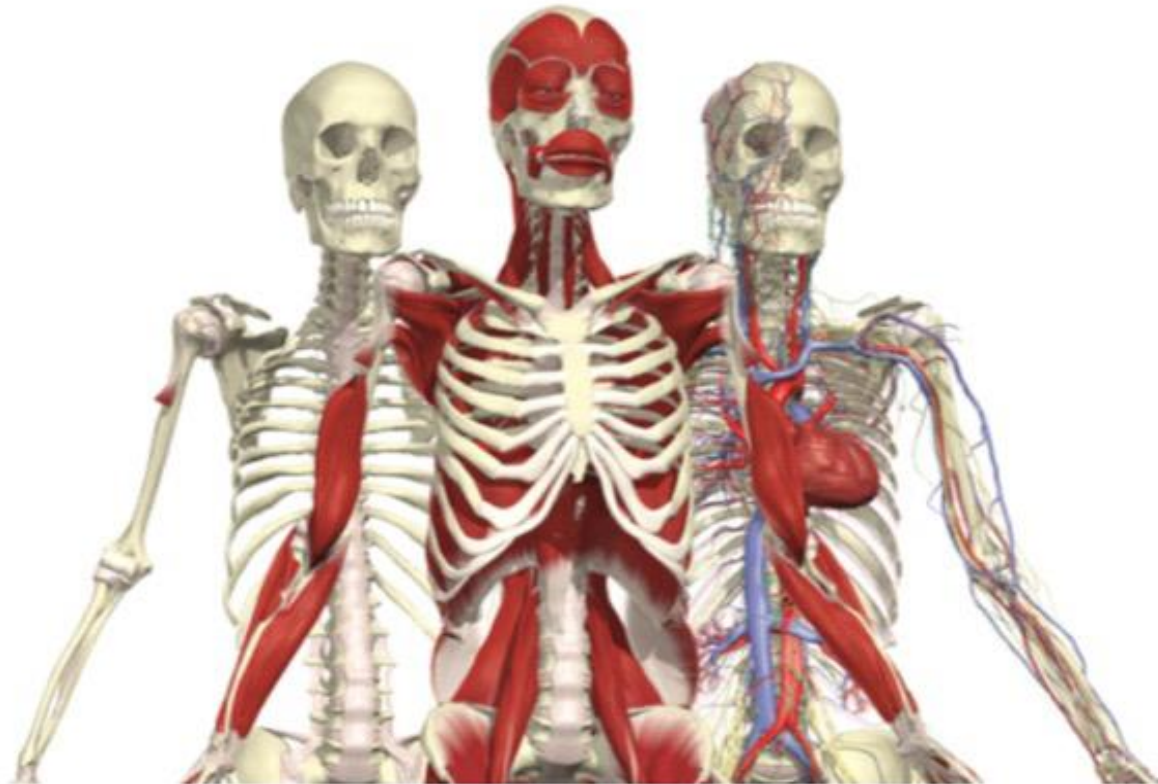

PRIMAL PICTURES



3D互动式解剖学数据库 使用指南

微信公众号



飞资得信息技术（上海）

PRIMAL PICTURES



内容

数据库首页.....	页数 3
Disease & Conditions 模块简介.....	页数 4
3D Atlas 模块简介.....	页数 5
3D Real - Time模块简介.....	页数 6
Functional Anatomy & Therapy 模块简介.....	页数 7
Anatomy & Physiology 模块简介.....	页数 8
Quizzing 模块简介.....	页数 9
Imaging 模块简介.....	页数 10
Clinical Specialties 模块简介.....	页数 11
Personal Profile 设定指南.....	页数 12-13
Smart Search智慧索搜操作指南.....	页数 14-16
Disease & Conditions 模块使用界面操作指南.....	页数 17-23
3D Atlas 模块使用界面操作指南.....	页数 24-30
3D Real – Time 模块使用界面操作指南.....	页数 31-48
Functional Anatomy & Therapy 模块使用界面操作指南.....	页数 49-55
Anatomy & Physiology 模块使用界面操作指南.....	页数 56-60
Quizzing 模块使用界面操作指南.....	页数 61-62
Imaging 模块使用界面操作指南.....	页数 63-69
Clinical Specialties 模块使用界面操作指南.....	页数 70-78

PRIMAL PICTURES首页

订购的模块

Disease & Conditions

3D Atlas

3D Real-time

Functional Anatomy and Therapy

Anatomy and Physiology

Quizzing

Imaging

Clinical Specialties

3D Real-time

English Chinese

Download on the App Store

GET IT ON Google Play

Now available for Android 13+

头部

脊柱

肩部

手部

胸部

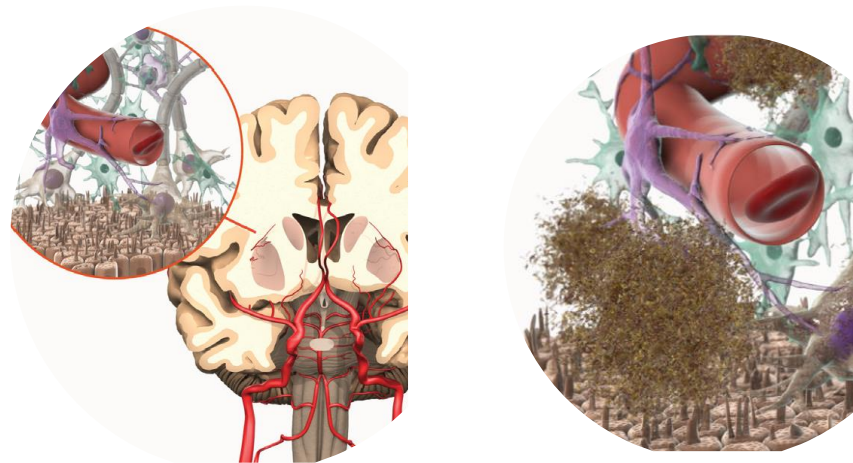
腹部

男性骨盆

访问网站: <http://www.anatomy.tv/>

Disease and Conditions模块简介 (单独购买)

- Primal Pictures的Disease & Conditions模块对于医疗照护产业的工作人员及学习者是一个重要的资源，该模块藉由图像、影音、动画及图表展现出疾病及生理失调的解剖结构，该资源，给予了教学者及学习者可以与原有PRIMAL中相关正常的解剖结构及生理状态讨论正常解剖及生理结构为何会逐渐失序的素材。
- Disease & Condition模块提供疾病生理及解剖信息，搭配原有PRIMAL索提供正常的解剖信息，可以满足教学上由正常到病理解剖图像的需求。
- 针对疾病病理信息提供文字、图片及影音课程资源，提供更完整的教学工具。
- 所有相关病理及解剖学信息均经过专家学者查核，符合教学重点。
- 透过ANATOMY.TV整合平台，可以一次性特定部位查询到正常及病理的图像及影音资源，可以更有效率应用。
- 超过80几种常见疾病说明



3D Atlas模块简介

该模块为局部解剖学的完整参考信息,分为9个模组

- 多种内容呈现方式：3D Anatomy、MRI、Slides、及Movie；
- 各人体构成均配有详尽的文字说明，以便读者可以快速了解各部位内容及解释。

PRIMAL'S 3D ATLAS OF HUMAN ANATOMY OF THE HEAD AND NECK

3D Views

- Head and neck
- Head
- Face
- Brain
 - Brain - overview
 - Cerebrum
 - Cerebellum
 - Brainstem
 - Meninges
 - Dural folds and sinuses
 - Ventricles of the brain

Slides

- Anatomy slides
- Clinical slides
- Dissection slides
- Cervical region of the spinal cord from the front
- Cranial fossae, with dura mater intact
- Deep dissection of the left half of the tongue, from the right
- Face: deep dissection, right infratemporal fossa and TMJ - mandible and adjacent structures removed
- Face: superficial dissection, the left parotid gland, facial nerve and muscles
- Left prevertebral region
- Left side of the neck, from the left and front
- Mouth and palate in sections: the inside of the

Dissection slides

- Head MRI
- Axial MR of the head and neck, slice 01
- Axial MR of the head and neck, slice 02
- Axial MR of the head and neck, slice 03
- Axial MR of the head and neck, slice 04
- Axial MR of the head and neck, slice 05
- Axial MR of the head and neck, slice 06
- Axial MR of the head and neck, slice 07
- Axial MR of the head and neck, slice 08
- Axial MR of the head and neck, slice 09

Axial MR of the head and neck, slice 03

Cerebrum

The cerebrum accounts for 85% of the brain and occupies the anterior and middle cerebral fossae. It is directly related to the cranial vault and is divided into two cerebral hemispheres that are joined at the bottom by the corpus callosum. The surface of the cerebrum is covered in a layer of grey matter; this cortex covers a core of white matter. Thick folds called gyri that form shallow grooves called sulci increase the surface area of the cerebrum. Several prominent sulci divide the cerebrum into 5 lobes;

- Frontal
- Parietal
- Temporal
- Occipital
- Insula

The cerebrum controls and integrates motor, sensory, and higher mental functions, such as thought, reason, emotion and memory.

Visible structures

Functional Anatomy and Therapy 模块简介

互动式功能解剖提供您观察肌肉功能，以及与骨骼和韧带的运动，内有超过70组完整骨架动画。

这个模块适合用在物理治疗、职业治疗的研究与发展上。

- 多种内容呈现方式：
3D Anatomy, Slides, Movies 及 Animations
- 涵括多种运动伤害专业参考资讯
- 影片及动画形式剖析运动过程中的肌肉受力及拉伸情况
- 详尽的文字阐述，并配有临床相关性说明

提供治疗领域的专业知识。

读者可从以下几个方面进行参考与了解：

Anatomy Trains (肌筋膜疼痛症候群脉络分布)

Massage and Manual Therapies (按摩与伸展照顾)

Exercise(运动)

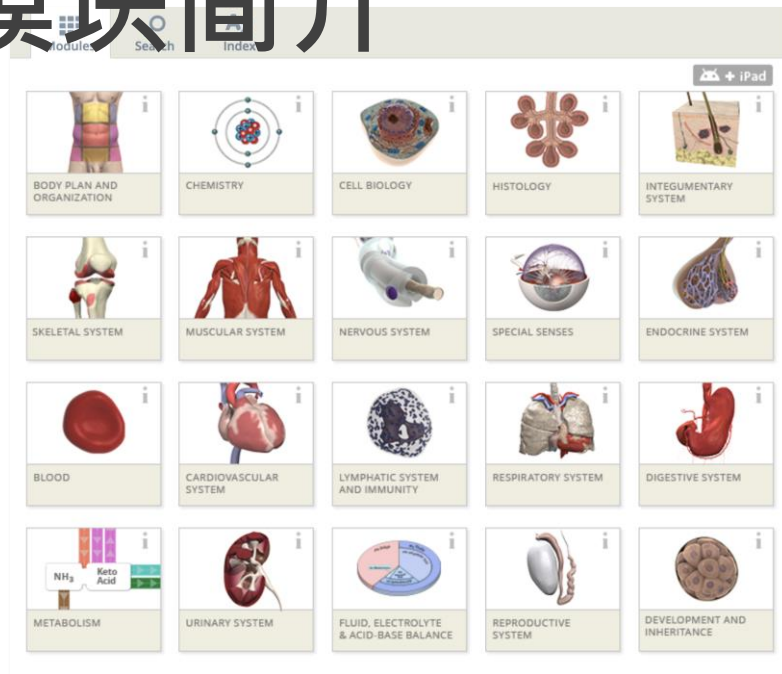Pilates(普拉提)

Yoga (瑜伽)

Resistance Training (抗阻力训练)

Anatomy and Physiology 模块简介

- 20个身体系统模组
- 辅助解剖学，生理组织学课程内容
- 多媒体学习取向：3D影像、综合说明文字、影片视频、叙述式动画及图解、发音指南、解剖图、投影片等
- 250 多个涵盖病理生理学的临床主题及案例研究
- 有关病因（病原学）、症状、诊断与治疗选项的综合临床信息



Photomicrograph of cardiac muscle

Striations

Nuclei

Cardiac muscle fibers

Intercalated disc

Cardiac muscle

Chemical synapse

Synapses

Learning objectives

On completing this topic, you should be able to:

- Distinguish between the different types of synapses.
- Label the parts of a synapse.
- Explain the release of neurotransmitters from the presynaptic neuron.
- Explain the possible effects of neurotransmitters on the postsynaptic membrane.
- Distinguish between spatial and temporal summation.
- List the major groups of neurotransmitters and

SYNAPSES AND NEUROTRANSMITTERS

The nervous system consists of vast circuits of interconnecting neurons, with each neuron communicating with the next via synapses.

A synapse is a specialized junction mediating the transfer of information between neurons. Synapses can be classified based on structure or function. Structurally there are axodendritic, neuromuscular, and neuroglanular synapses, and functionally, there are electrical and chemical synapses.

Electrical synapses connect cells directly and are found mainly in the CNS and cardiac muscle. Chemical

CLINICAL

Clinical

Disease processes commonly implicated in disorders of the skeletal system include localized inflammation, infection, degenerative change, trauma, and more widespread metabolic and endocrine disorders. Clinicians who use medications and non-surgical forms of treatments for skeletal system disorders are called rheumatologists. If surgical treatments are required, then these are carried out by specialists called orthopedic surgeons.

Bone metastasis

Overview

Metastatic disease is the spread of disease (cancer or infection) from its primary (or original) site to another organ. Metastases indicate an advanced stage of cancer and by the time of their diagnosis they are often multifocal conferring a poor prognosis. Common sites of metastasis from solid organ tumors include the bone, lung, liver, and brain.

Bone metastases are the most common malignancy of the skeleton.

Causes

Original, or primary, tumors that usually metastasize to the bone are, in order of frequency, breast, prostate, lung, kidney, or thyroid. Common sites of bony metastases include the vertebrae, pelvis, ribs, limbs (proximal part of the humerus or the femur), and the skull.

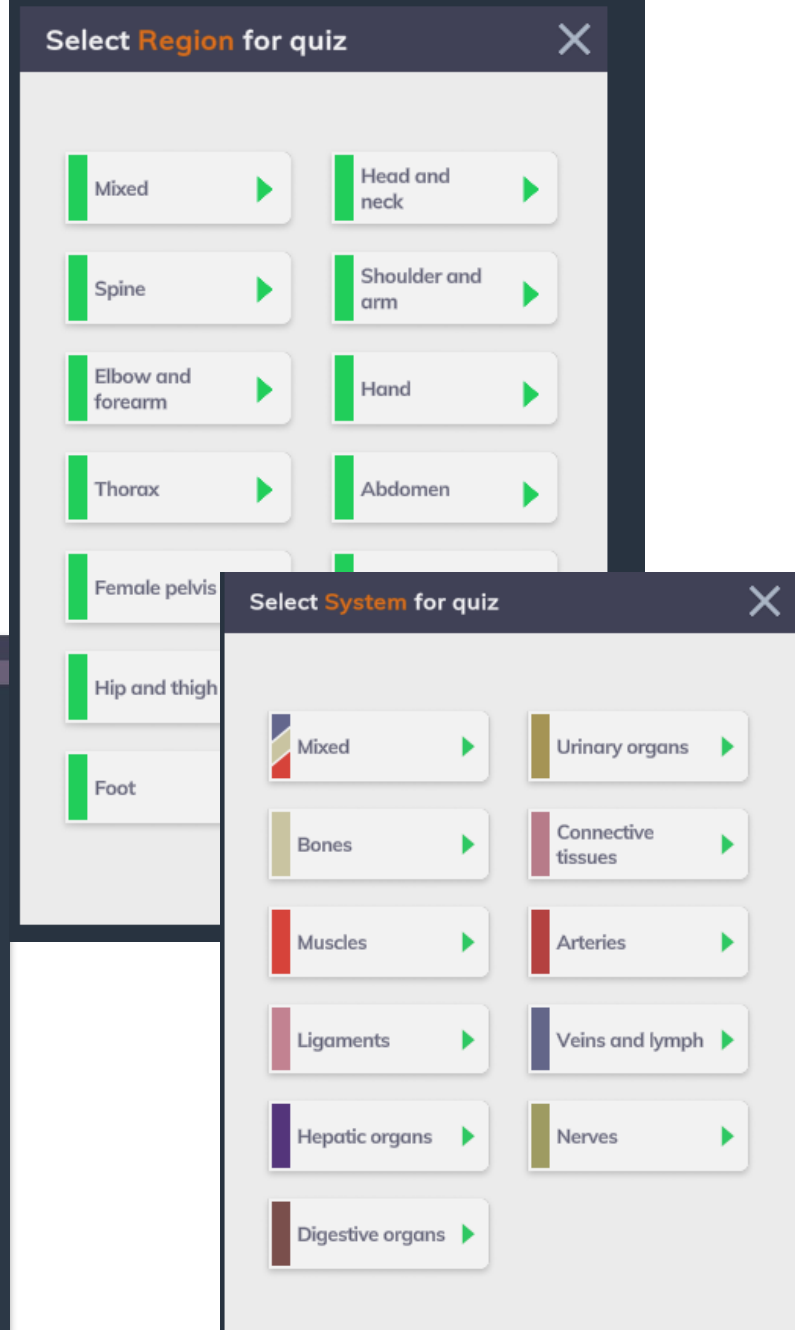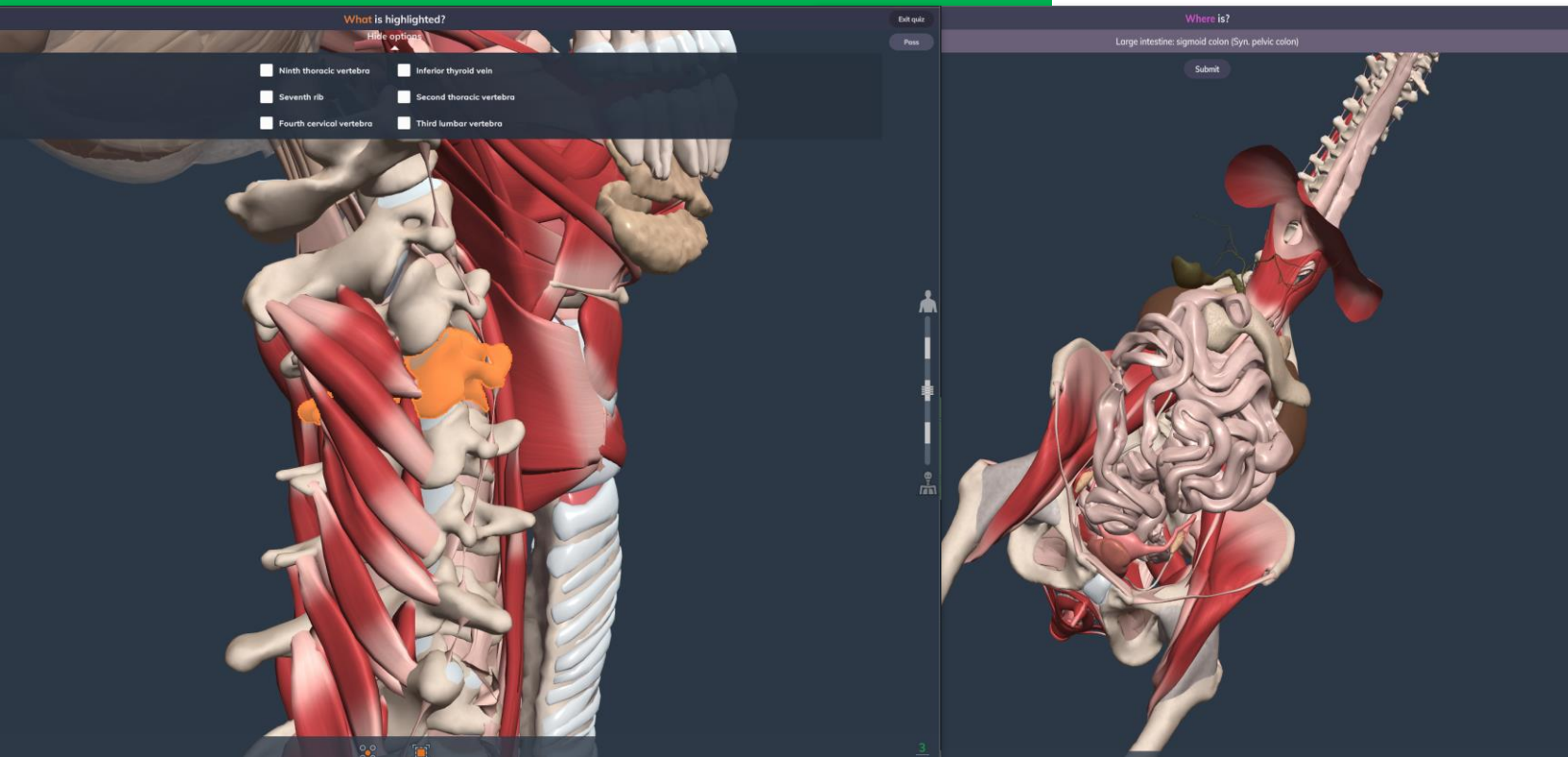
The pathological process is initiated when tumor cells from the primary cancer enter the bloodstream. The cells migrate to the bony vasculature, where they exit and adhere to the endosteal surface. As a consequence of this, the cells proliferate and grow into the medullary cavity.

The presence of metastases affects the process of bone remodeling by causing either an increase in osteoclastic activity (and hence bone resorption through osteolysis) or an increase in osteoblastic activity, leading to an increase in bone formation (osteoblastic). Alternatively,

Osteolytic lesions, characterized by holes within the bone structure, and osteosclerotic lesions, containing areas of new bone formation, may need to be further examined with additional

Quizzing 模块简介

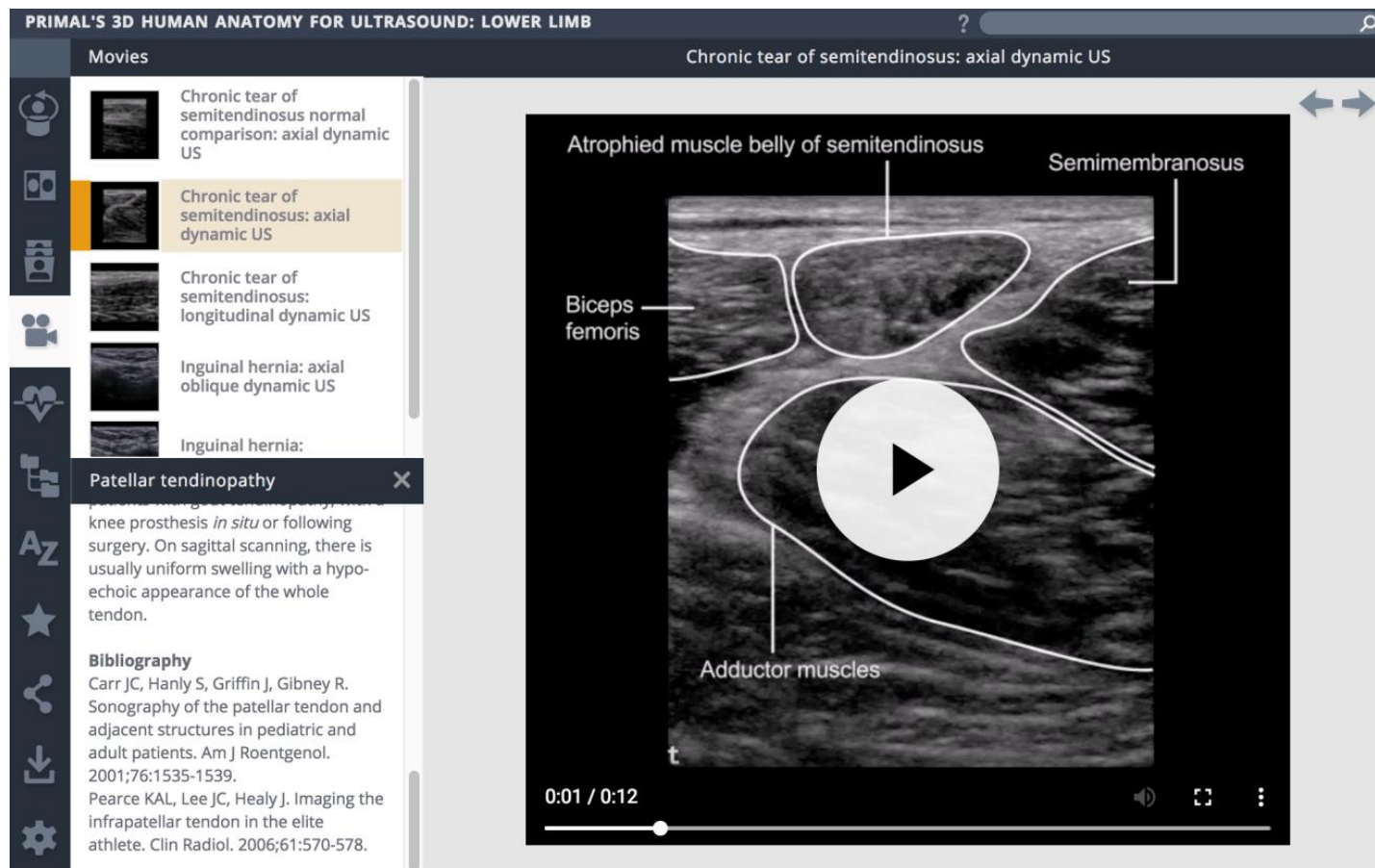
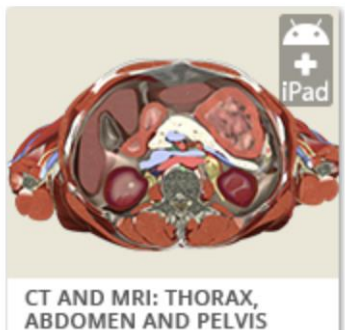
提供丰富的自我检测题目，
学生可以反复练习。



Imaging模块简介

提供丰富的人体超声波、CT、及MRI图片。

- 多维查看方式：
横向、纵向、及冠状切面
- 对应3D解剖图像还原
- 多层次结构查看
- 详细的文字说明



PRIMAL'S 3D HUMAN ANATOMY FOR ULTRASOUND: LOWER LIMB

Chronic tear of semitendinosus: axial dynamic US

Atrophied muscle belly of semitendinosus

Semimembranosus

Biceps femoris

Adductor muscles

0:01 / 0:12

Movies

- Chronic tear of semitendinosus normal comparison: axial dynamic US
- Chronic tear of semitendinosus: axial dynamic US
- Chronic tear of semitendinosus: longitudinal dynamic US
- Inguinal hernia: axial oblique dynamic US
- Inguinal hernia:

Patellar tendinopathy

knee prosthesis *in situ* or following surgery. On sagittal scanning, there is usually uniform swelling with a hypo-echoic appearance of the whole tendon.

Bibliography

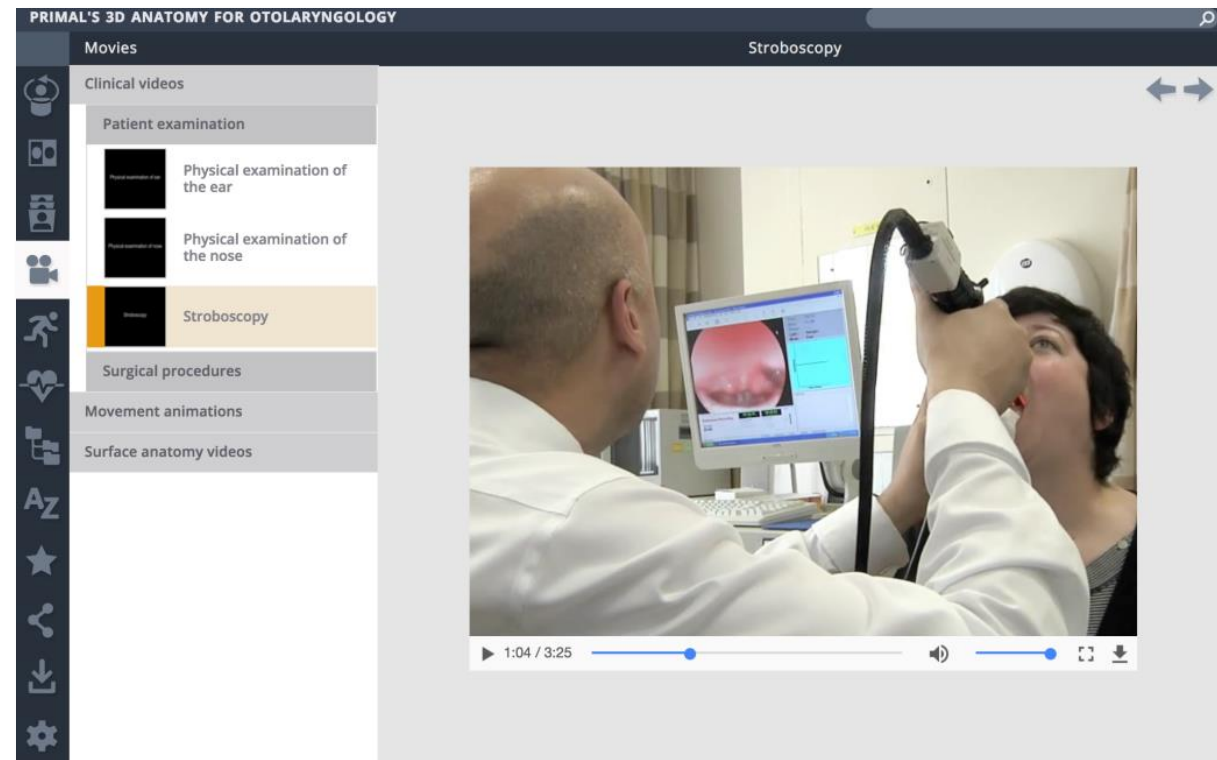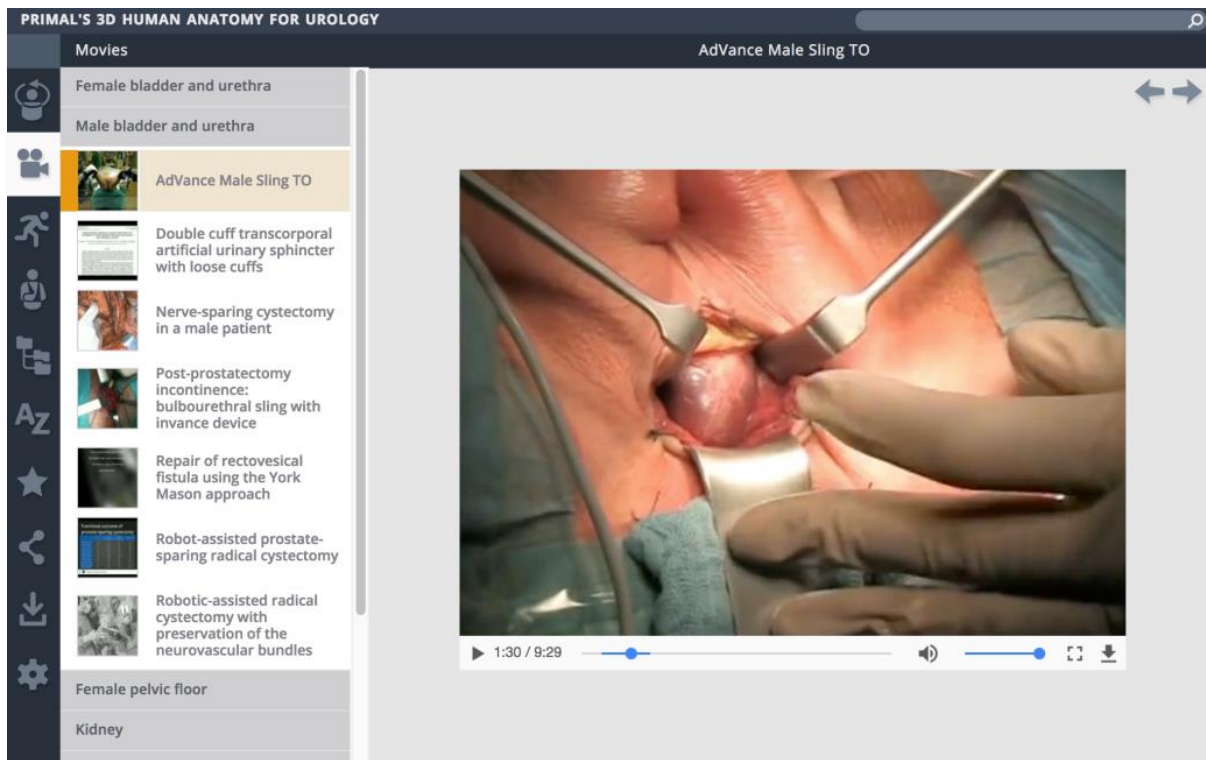
Carr JC, Hanly S, Griffin J, Gibney R. Sonography of the patellar tendon and adjacent structures in pediatric and adult patients. *Am J Roentgenol.* 2001;76:1535-1539.

Pearce KAL, Lee JC, Healy J. Imaging the infrapatellar tendon in the elite athlete. *Clin Radiol.* 2006;61:570-578.

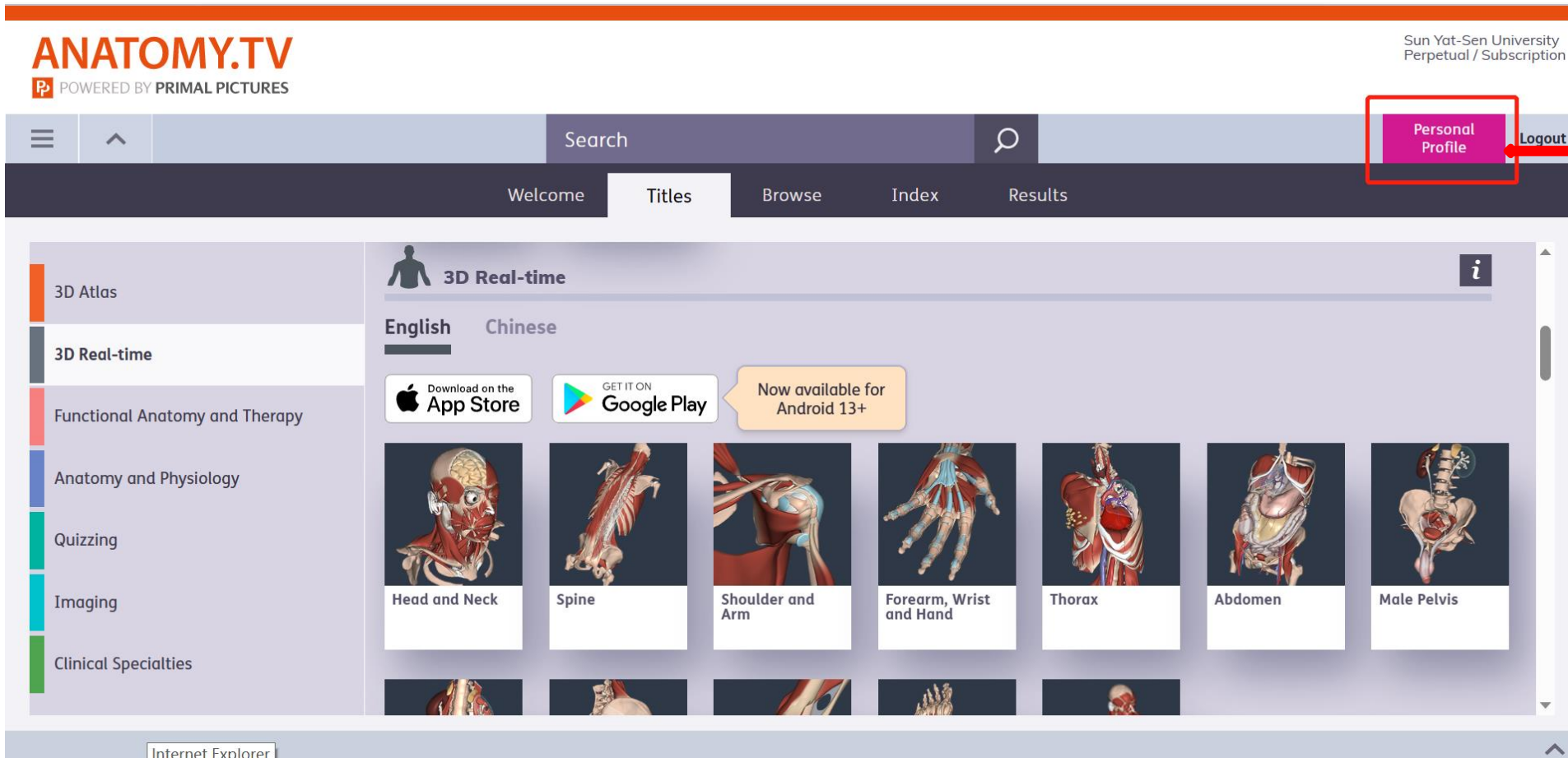
Clinical Specialties 模块简介

提供多种临床专科诊疗参考资料。為多种临床专科提供更详尽资料信息(口腔科，耳鼻喉科，泌尿科...)

同时还加入临床诊疗示范视频，以及相关手术影片。



数据库使用界面-Personal Profile设定指南



可以创建
Personal
Profile

访问网站: <http://www.anatomy.tv/>

数据库使用界面-Personal Profile设定指南

You are logged-in as Sun Yat-Sen University

Want to **customize** Anatomy.tv by creating a **Personal Profile**?

Create Profile

Find out more about Personal Profiles >>

Already have your own Profile?
Sign in to your Profile

Don't want to create your own Profile?
Continue to Anatomy.tv

Create your **Personal Profile** 1 of 2

Email
Email

Confirm email
Confirm email

Password
Password

Confirm password
Confirm password

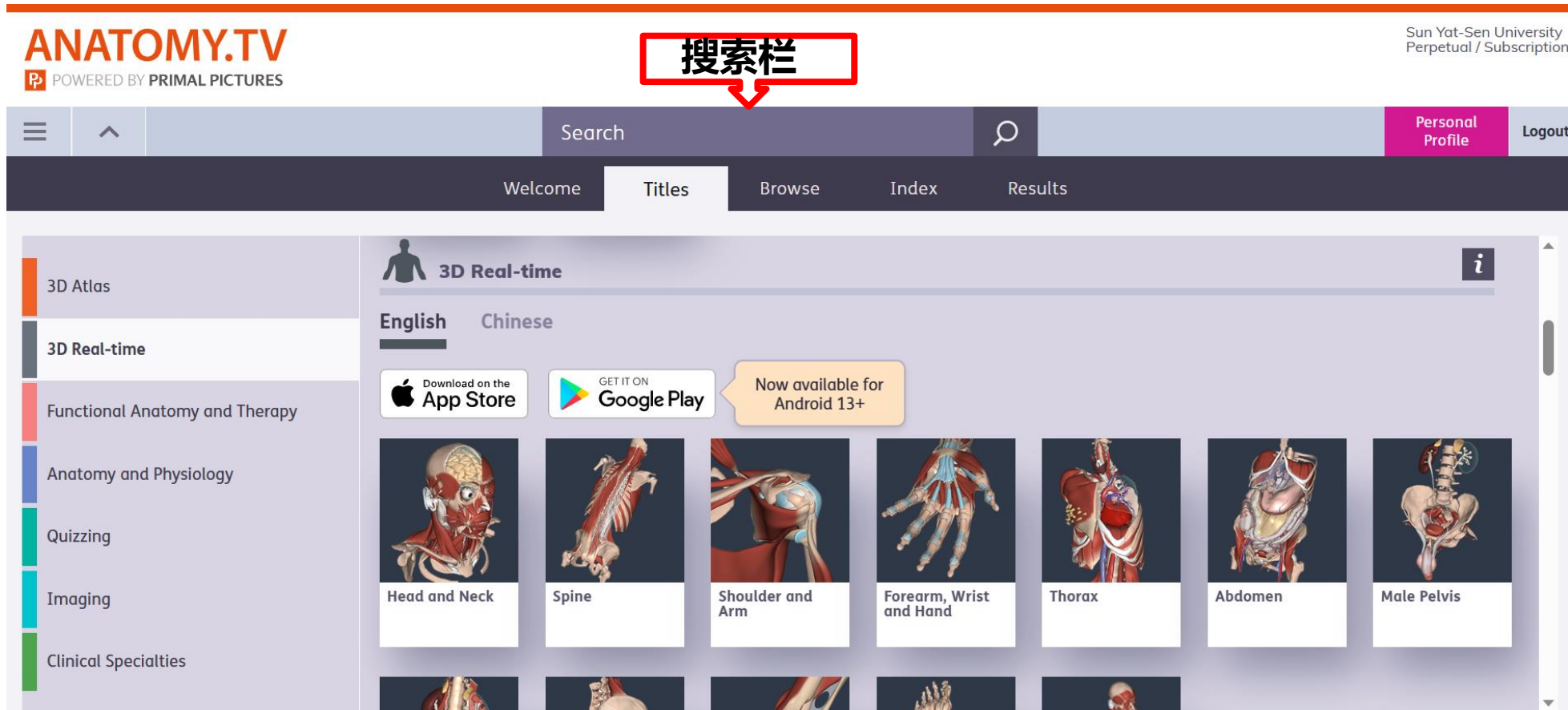
Next

Cancel

< Back

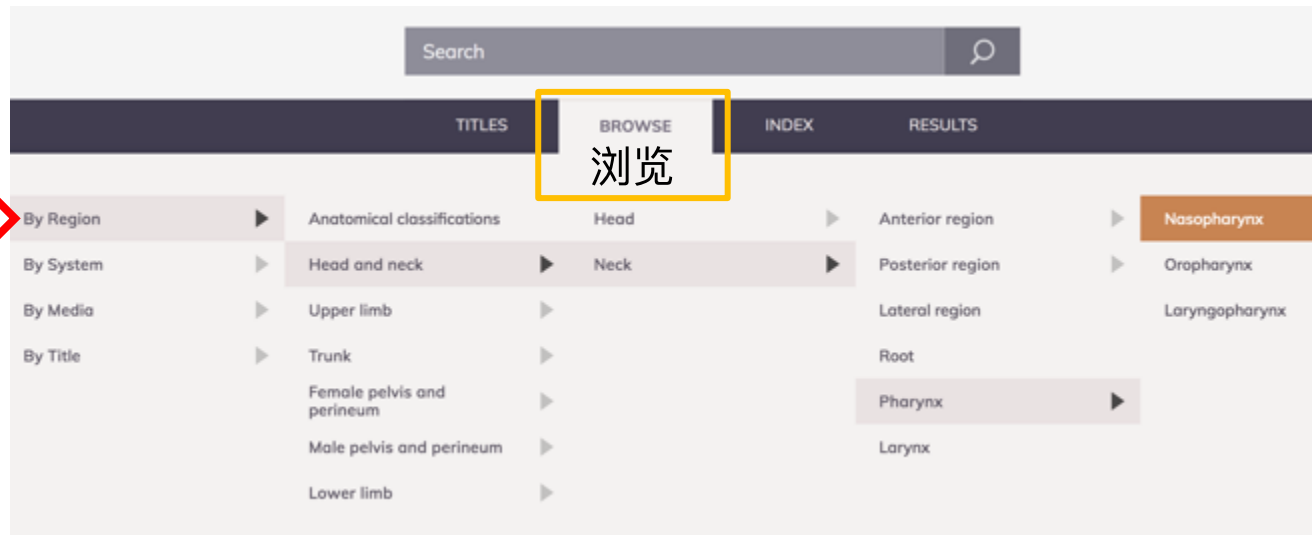
创建Personal Profile后就可以把自己创作的资料或想要储存的资料放在Personal Profile里，可以有效率地使用试用数据库内容

数据库使用界面 – 搭配Smart Search智能搜索



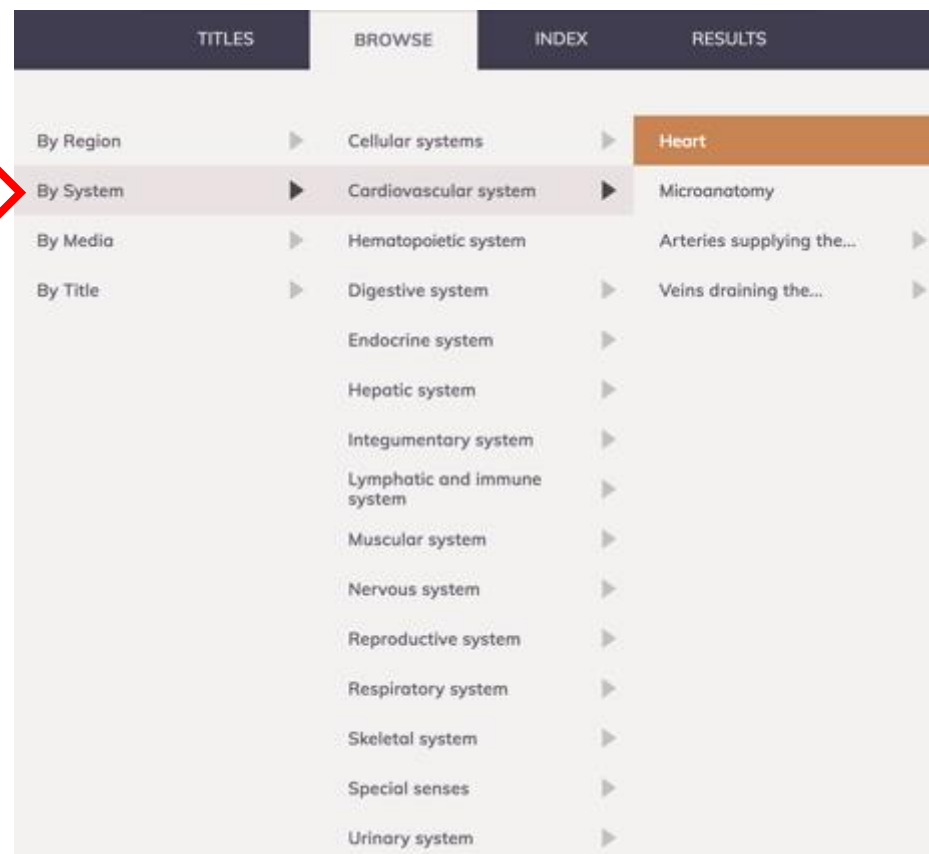
输入关键字搜索后，将从订购的所有模块中，快速查询出与此相关内容。

1



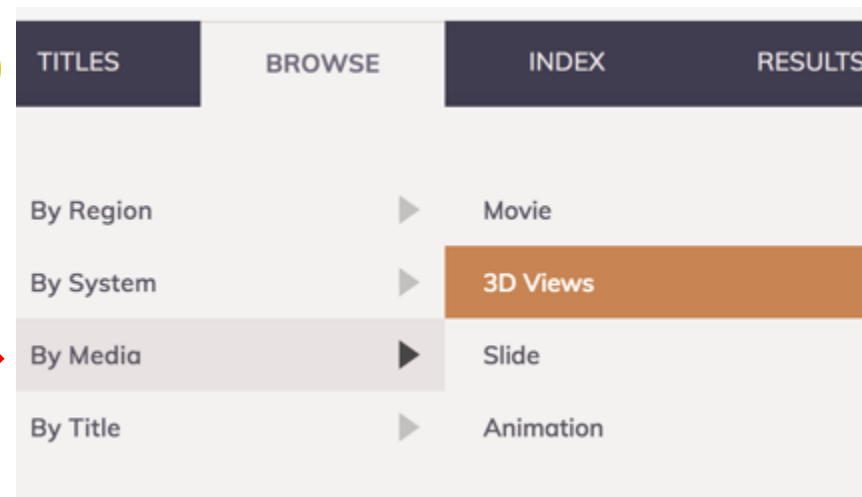
部位

2



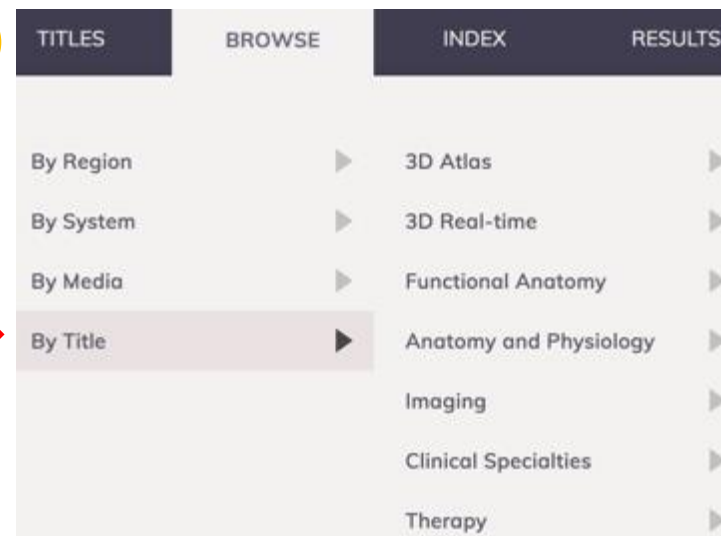
系统

3



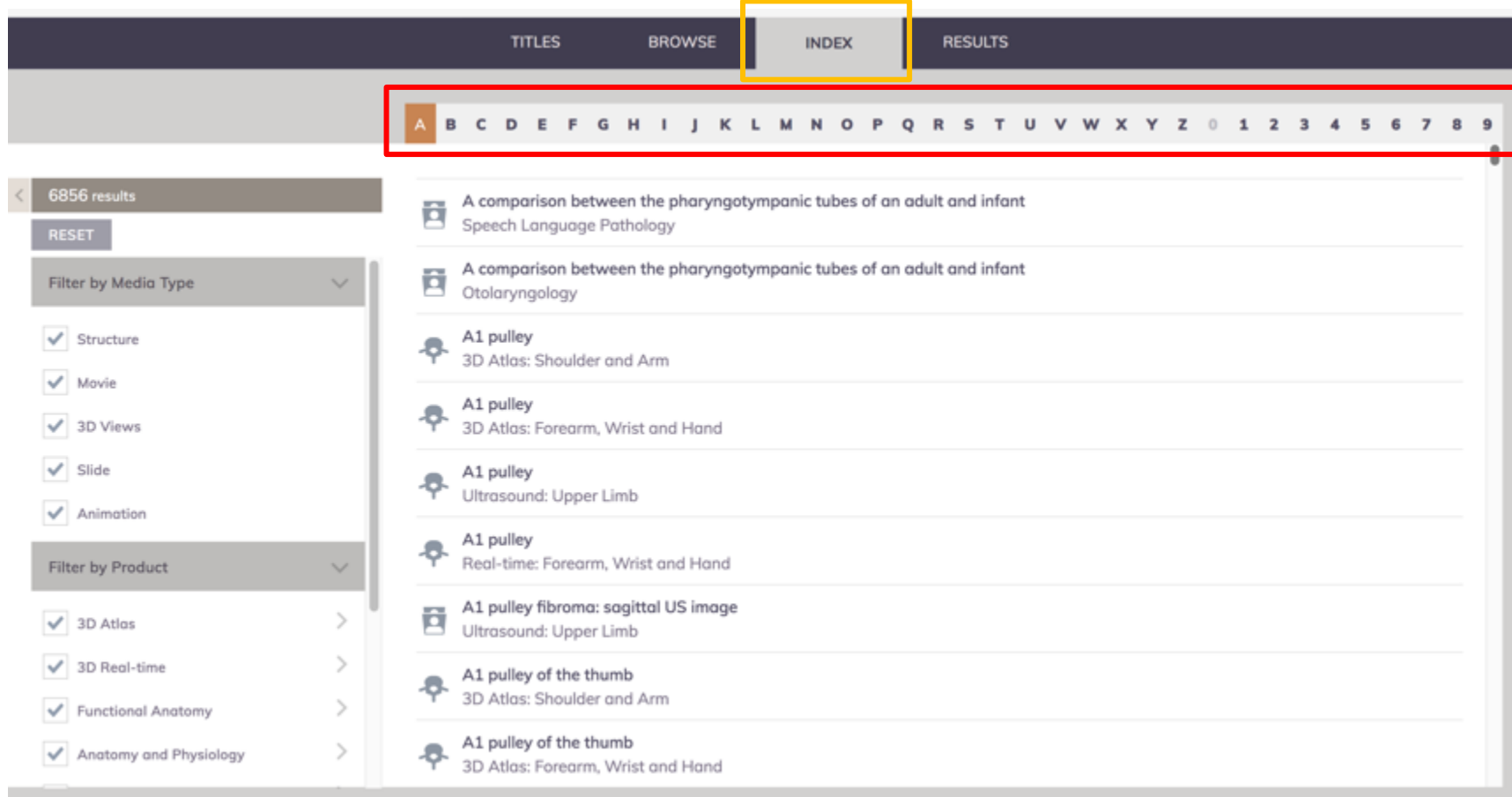
媒体类型

4



模块

根据首字母快速查询



筛选栏：可以继续根据媒体类型、模块进行搜索

访问网站：<http://www.anatomy.tv/>

Disease & Conditions 模块使用界面

ANATOMY.TV
POWERED BY PRIMAL PICTURES

Primal Pictures is on Instagram!
Click **here** to watch our anatomists compete in our new 3D Anatomy Quiz app and follow us for more great videos, quizzes, competitions and more!

Search

WELCOME | TITLES | **BROWSE** | INDEX | RESULTS

Disease & Conditions

- 3D Atlas
- 3D Real-time
- Anatomy and Physiology
- Functional Anatomy and Therapy
- Quizzing
- Imaging

Disease & Conditions

Disease & Conditions

Disease & Conditions 模块使用界面 – 左方控制区

The screenshot displays the 'Disease & Conditions' module interface. The left sidebar, labeled 'Specialties', lists various medical fields: Accidents and injuries (1), Cardiology, Chiropractic, Dentistry, Endocrinology, Gastroenterology, Gynecology, and Hepatology. The central area features a video player titled 'What is an Anterior Cruciate Ligament Injury?' with a duration of 0:00 / 7:28. The right-hand panel, titled 'Accidents and injuries', contains a list of conditions (2) such as ACL injury, Ankle injuries, Golfer's elbow, Hamstring origin tendinopathy, and Whiplash. Below this list, a section titled 'ANTERIOR CRUCIATE LIGAMENT INJURY' (3) provides a video thumbnail and text stating: 'Approximately 5.35 million individuals have an anterior cruciate ligament injury each year worldwide.'

① 分科

② 主题表列

③ 主题内容

Disease & Conditions 模块使用界面 – 左方控制区

The screenshot displays a medical information interface for "ACL injury". The interface is divided into several sections:

- Left Sidebar (Specialties):** A vertical list of medical specialties with corresponding icons. The "Accidents and injuries" category is highlighted in yellow. Other specialties include Cardiology, Chiropractic, Dentistry, Endocrinology, Gastroenterology, Gynecology, and Hepatology.
- Top Header:** "DISEASE AND CONDITIONS" with a search icon on the right.
- Central Panel:** Titled "ACL injury", it features a large 3D anatomical model of a knee joint. A red dashed box highlights a video player embedded in this panel. The video player shows a thumbnail of the knee model and the title "What is an Anterior Cruciate Ligament Injury?". The video progress is at 0:00 / 7:28. A red arrow points from the video thumbnail in the right-hand panel to the video player in the central panel.
- Right-Hand Panel:** Titled "ACL injury", it contains a "Disease and Conditions" header with a plus sign. Below this is the text "ANTERIOR CRUCIATE LIGAMENT INJURY" followed by the Chinese characters "影片" (Video). A red box highlights a video thumbnail showing a close-up of the knee joint. Below the thumbnail is a block of text providing statistics and facts about ACL injuries.

Text in the Right-Hand Panel:

Approximately 5.35 million individuals have an **anterior cruciate ligament injury** each year worldwide.

This type of injury is most commonly seen in individuals between the ages 15 and 45.

Women are five times more likely to develop the injury compared to men.

An anterior cruciate ligament injury is a **tear** or **sprain** in the anterior cruciate ligament in the knee.

Disease & Conditions 模块使用界面 – 左方控制区

The screenshot displays a medical education interface. On the left is a sidebar with a search bar and a list of specialties: Accidents and injuries, Cardiology, Chiropractic, Dentistry, Endocrinology, Gastroenterology, Gynecology, and Hepatology. The main area is titled 'ACL injury: healthy anterior knee' and features a 3D anatomical diagram of a knee joint with labels for the Femur, Patella, Medial collateral ligament, Lateral collateral ligament, Medial meniscus, Lateral meniscus, Tibia, and Fibula. On the right, a panel titled 'ACL injury' contains text about the knee joint, including the heading 'THE KNEE JOINT 主题内文', a definition of the knee joint as a modified hinge joint, and a list of four key ligaments: ACL, PCL, Medial collateral ligament, and Lateral collateral ligament. Below this list, there are two small images of the knee joint and a section titled 'ACL' with a description of its location and function.

DISEASE AND CONDITIONS

Specialties

Accidents and injuries

Cardiology

Chiropractic

Dentistry

Endocrinology

Gastroenterology

Gynecology

Hepatology

ACL injury: healthy anterior knee

ACL injury

Disease and Conditions

THE KNEE JOINT 主题内文

The knee is a complex joint that is formed by two separate joints: the **femoropatellar joint**, between the patella and the femur, and the **femorotibial joint**, between the femur and the tibia.

The knee joint is a **modified hinge joint**. This means that along with the normal range of flexion and extension, it can also undergo a limited range of internal and external rotation.

Knee stability is maintained by four key ligaments:

- Anterior cruciate ligament (ACL)
- Posterior cruciate ligament (PCL)
- Medial collateral ligament
- Lateral collateral ligament

ACL

The ACL extends from the anterior intercondylar region of the tibia to the lateral femoral condyle.

This ligament resists anterior

Disease & Conditions 模块使用界面 – 左方控制区

The screenshot displays the 'Disease & Conditions' module interface. The main content area shows a search for 'ACL injury: healthy anterior knee' and 'ACL injury'. The central image is a 3D anatomical model of a knee joint with labels: Femur, Patella, Medial collateral ligament, Lateral collateral ligament, Medial meniscus, Lateral meniscus, Tibia, and Fibula. The right sidebar contains text about 'THE KNEE JOINT' and a list of four key ligaments: Anterior cruciate ligament (ACL), Posterior cruciate ligament (PCL), Medial collateral ligament, and Lateral collateral ligament. Below this is a section for 'ACL' with a description: 'The ACL extends from the anterior intercondylar region of the tibia to the lateral femoral condyle.'

左方控制区 (Left Control Area):

- Index:** A navigation menu with 'Index' selected.
- FILTERS:** A section for filtering results by resource type. The 'AZ' icon is highlighted with a red dashed box. The filters listed are: Specialties (checked), Slides (unchecked), Pdf (checked), Movies (checked), and Condition Articles (checked). The text '资源类型' (Resource Type) is overlaid in red.
- RESULTS:** A list of search results. The first two results, 'A' and 'B', are highlighted. The text '主题名称表列' (Topic Name List) is overlaid in red.

Disease & Conditions 模块使用界面 – 左方控制区

The screenshot displays the 'Disease and Conditions' module interface. The main content area shows a 3D anatomical model of a healthy anterior knee with labels for the Femur, Patella, Medial collateral ligament, Lateral collateral ligament, Medial meniscus, Lateral meniscus, Tibia, and Fibula. The sidebar on the right contains text about 'THE KNEE JOINT' and 'ACL injury', along with images of the knee joint and a list of ligaments.

左方控制区 (Left Control Area):

- Size:** 960 x 720
- LMS/VLE link style:** Canvas
- GENERATE CODE:** 产生快速链接网页语法 (Generate code to quickly link web syntax)
- Code:**

```
<iframe src="https://www-anatomy-tv.sw.lib.csmu.edu.tw/anatomy/gotoview.aspx?embeddedcode=DA9975" width="960" height="720"></iframe>
```
- COPY CODE:** 复制代码

Disease & Conditions 模块使用界面 – 左方控制区

DISEASE AND CONDITIONS

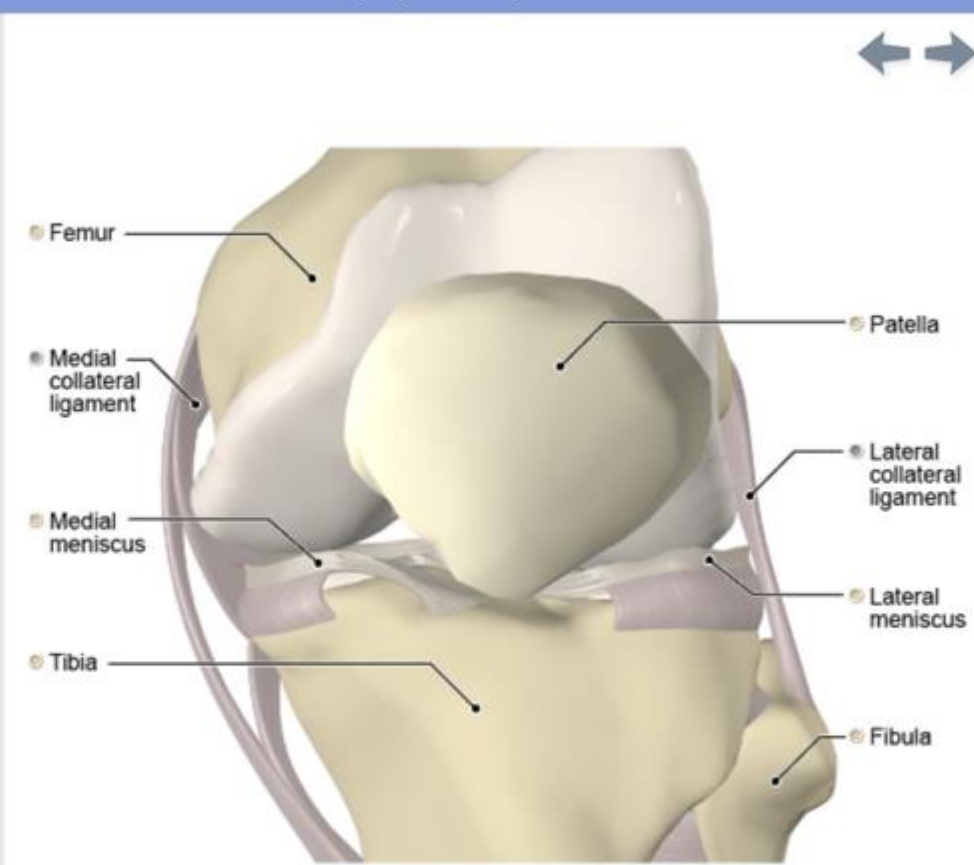
Save

SAVE IMAGE SAVE TOPIC TEXT SAVE TOPIC PDF

图片 文本文件 讲义文件

下载资源

ACL injury: healthy anterior knee



ACL injury

Disease and Conditions

THE KNEE JOINT

The knee is a complex joint that is formed by two separate joints: the **femoropatellar joint**, between the patella and the femur, and the **femorotibial joint**, between the femur and the tibia.

The knee joint is a **modified hinge joint**. This means that along with the normal range of flexion and extension, it can also undergo a limited range of internal and external rotation.

Knee stability is maintained by four key ligaments:

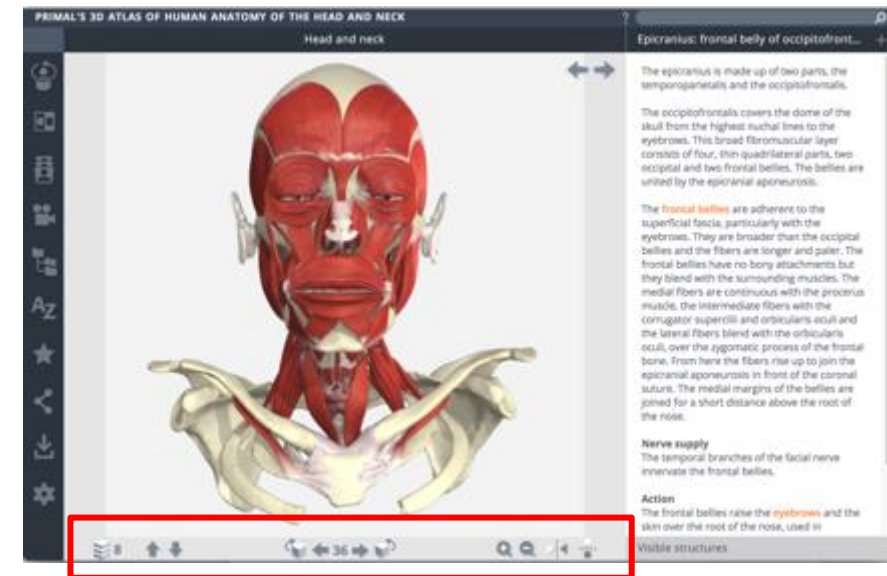
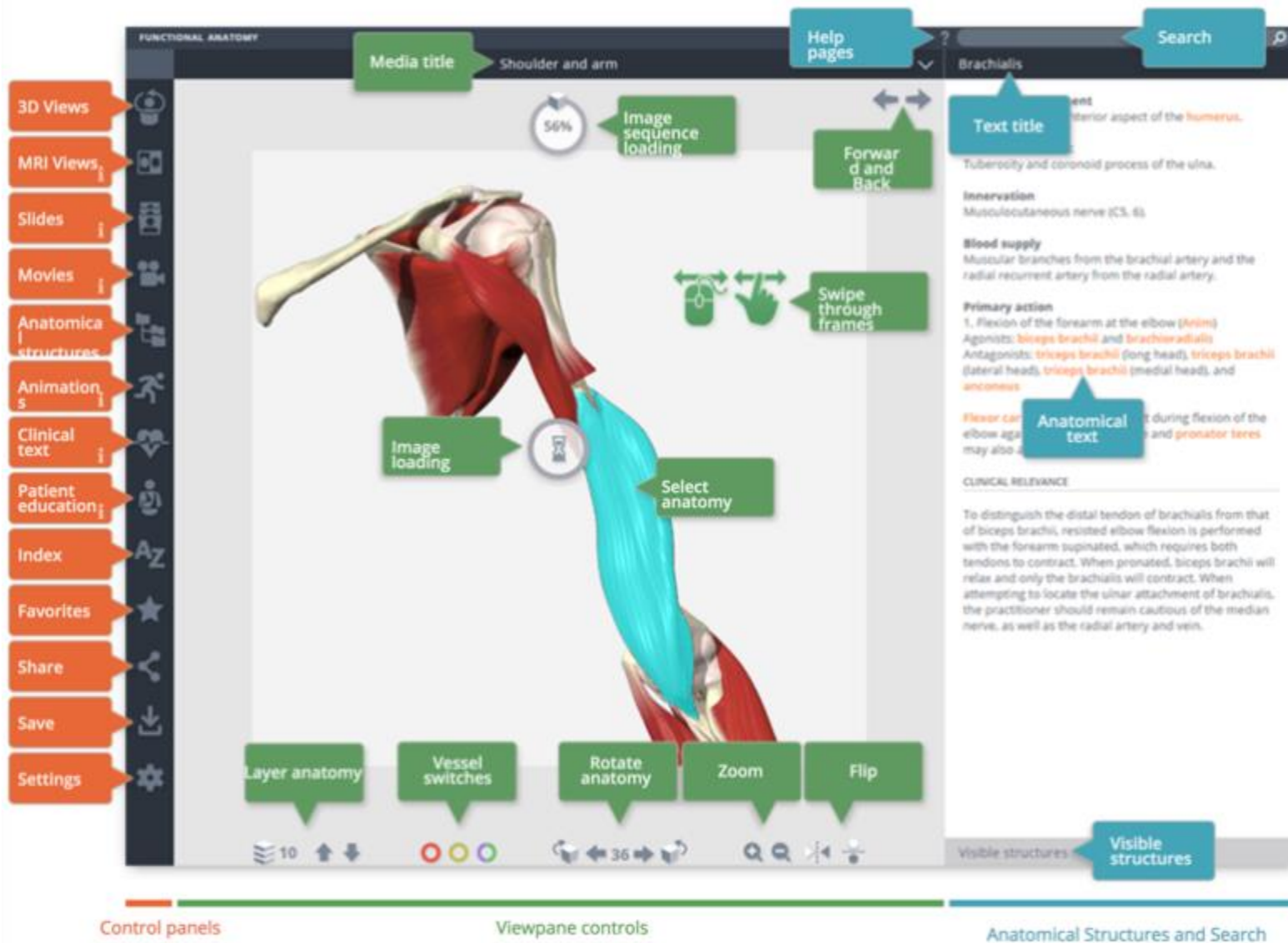- Anterior cruciate ligament (ACL)
- Posterior cruciate ligament (PCL)
- Medial collateral ligament
- Lateral collateral ligament

ACL

The ACL extends from the anterior intercondylar region of the tibia to the lateral femoral condyle.

This ligament resists anterior

3D Atlas模块使用界面 — 操作说明



解剖图片控制面板位於页面下方

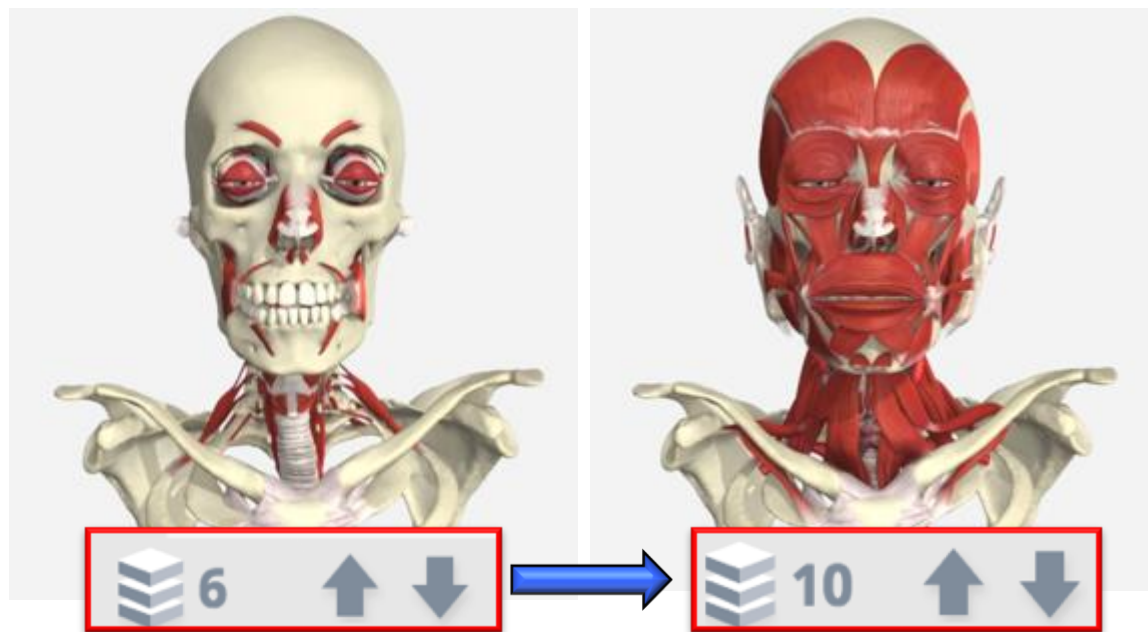
层次控制

旋转控制

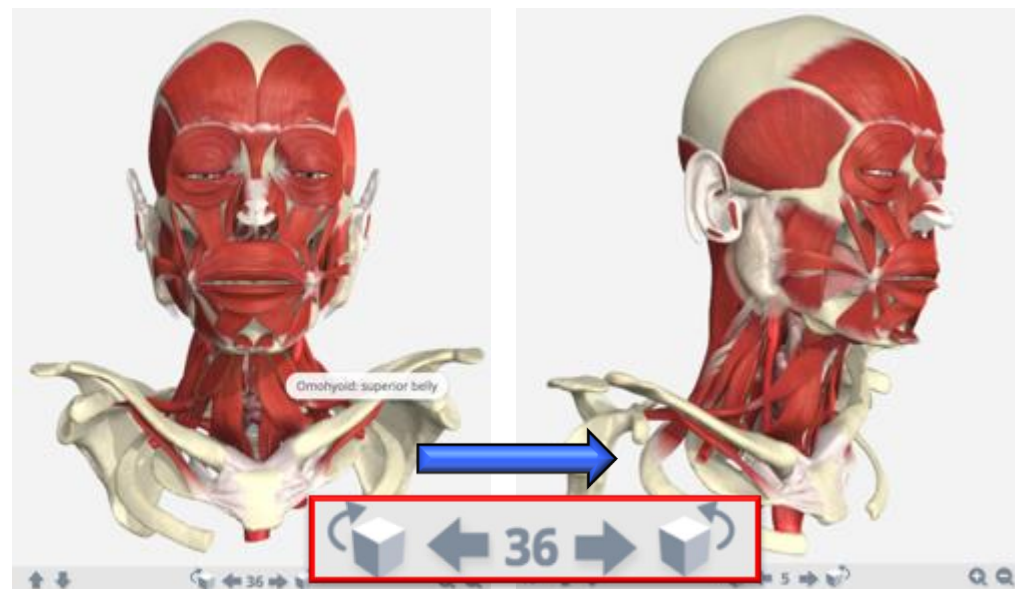
放大缩小控制

左右 / 上下颠倒

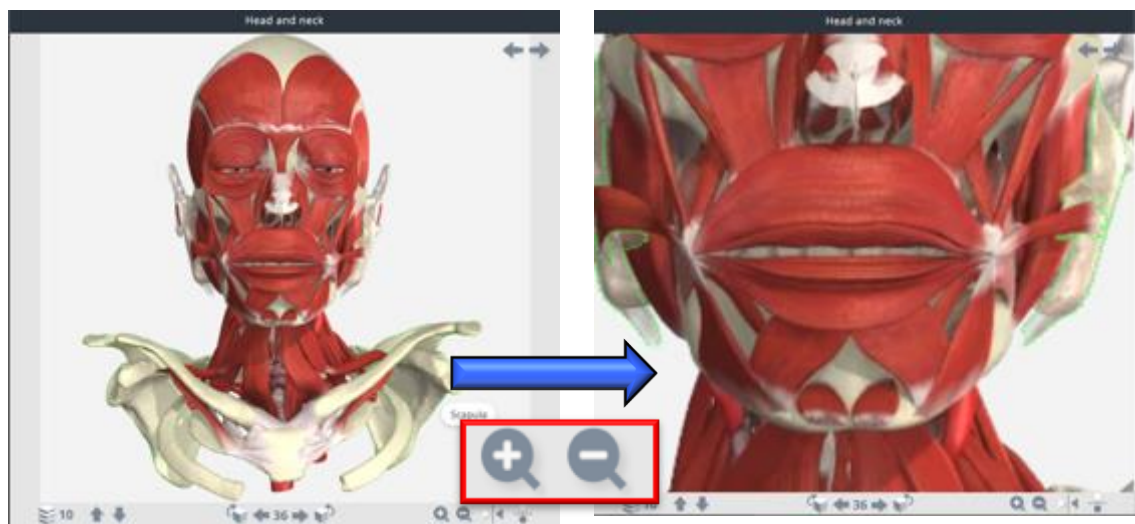
■ 不同的层次(Layer)



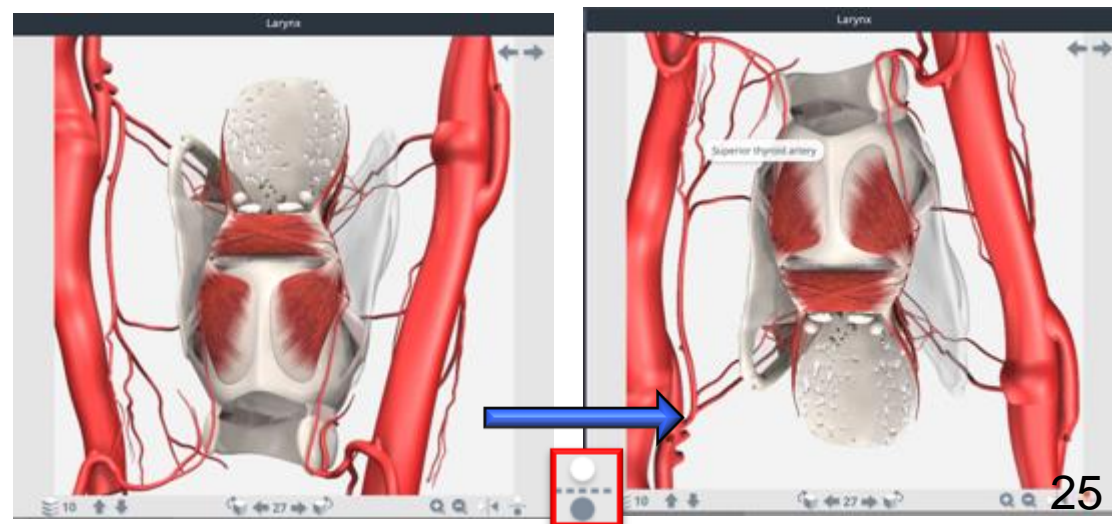
■ 不同的角度



■ 放大、缩小

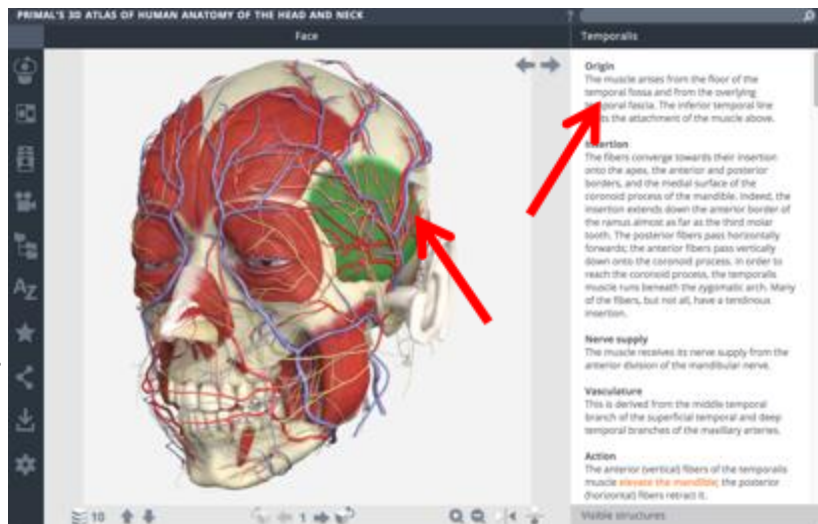


■ 上下、左右颠倒呈现

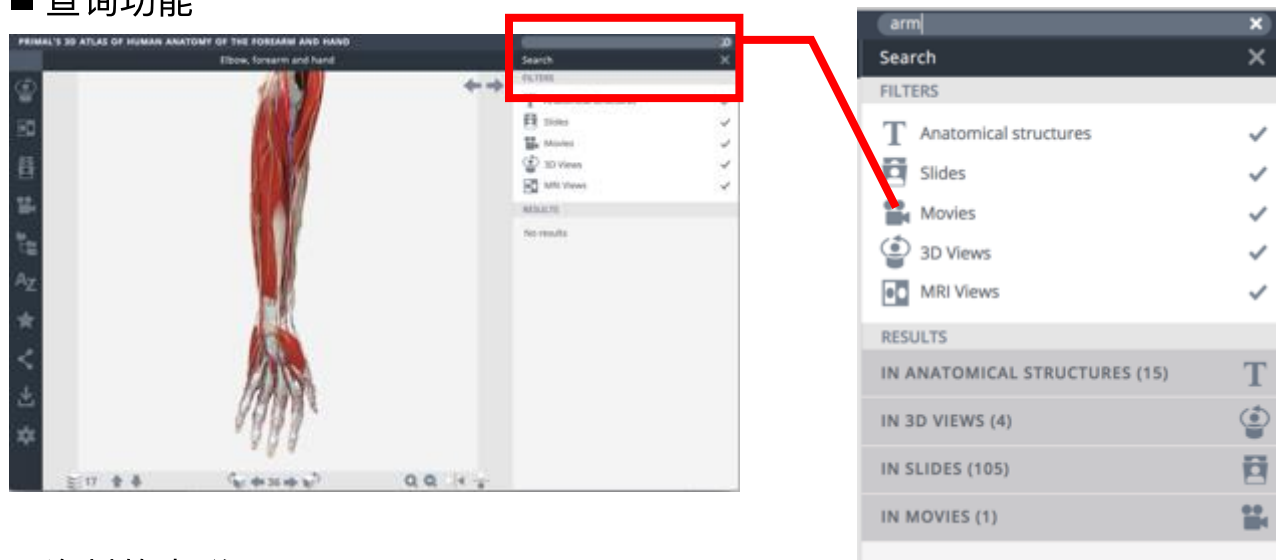


3D Atlas模块使用界面 — 操作说明

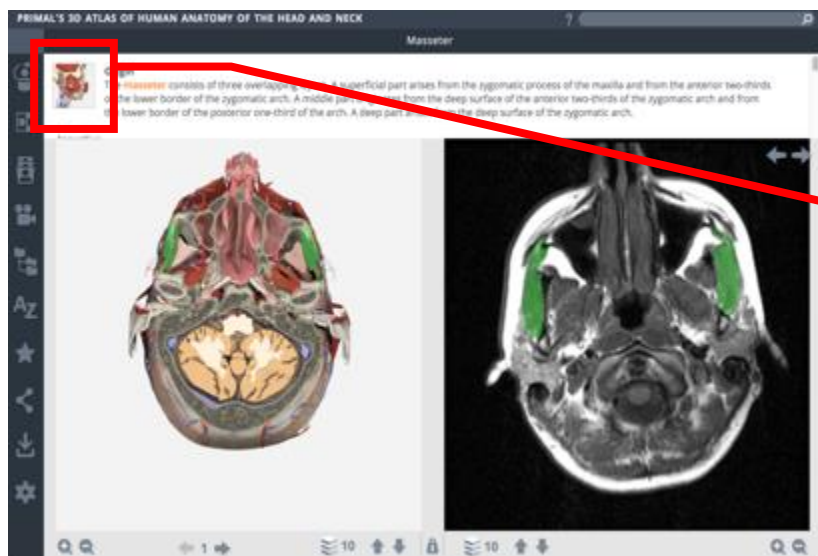
■ 在3D图片
点选一个部位，该部位
将会变色标
明（图中绿
色区域），
并在右方提
供详细介绍。



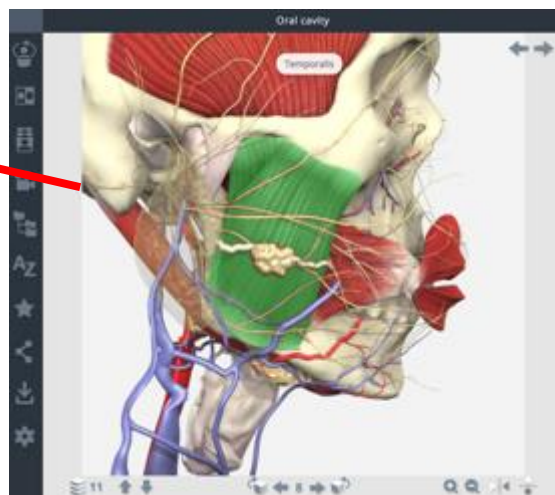
■ 查询功能



■ 对比3D立体
图像与准确的
MRI图像



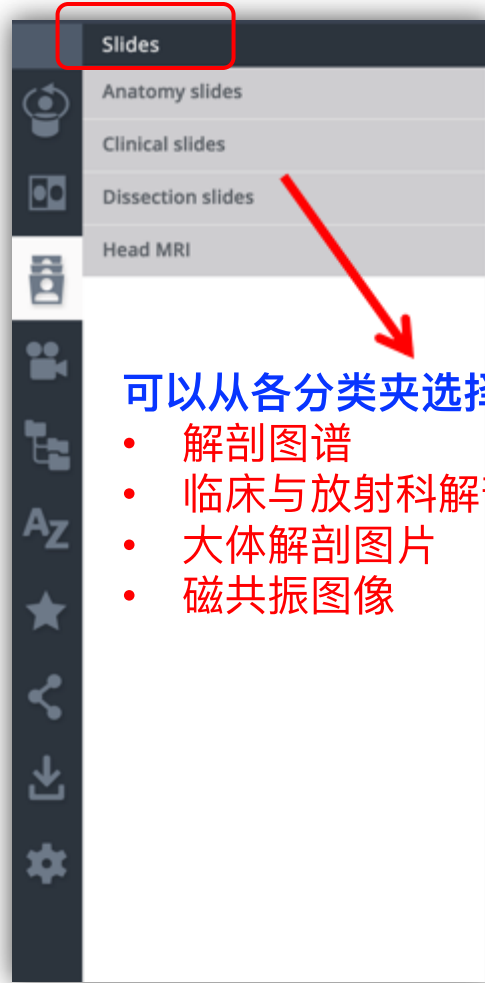
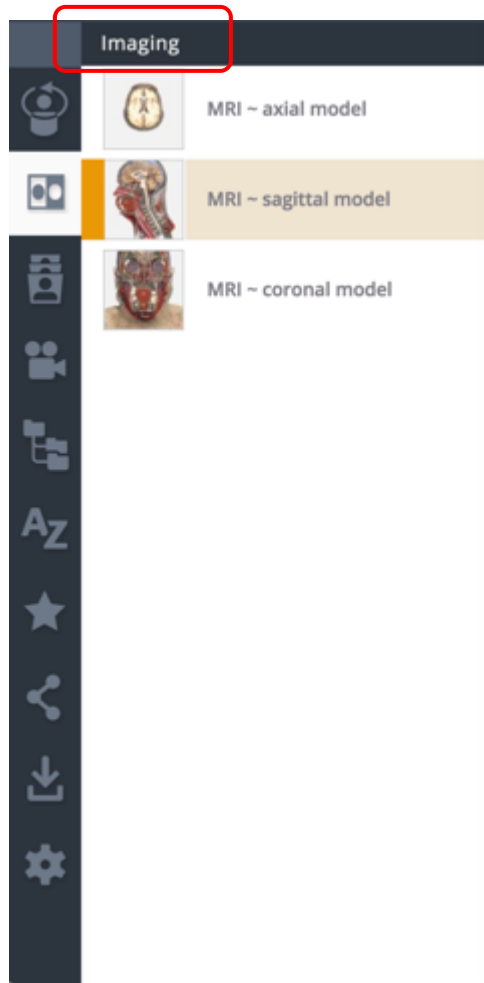
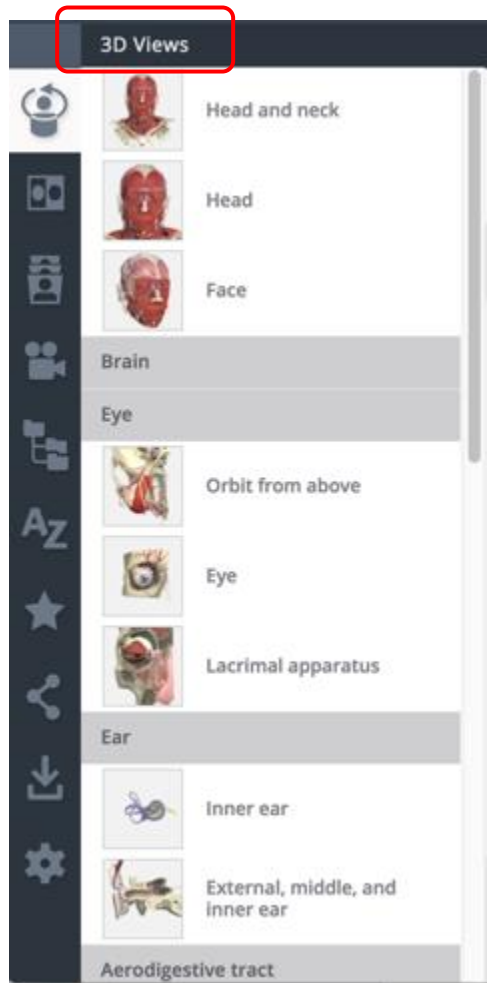
■ 资料的串联



在3D图点选一
部位后，MRI
图片中该部位
会同步选取，
并提供详细文
字解说。（解
说中的红字可
链接开启图片、
影片、以及更
多的详细说明
内容）

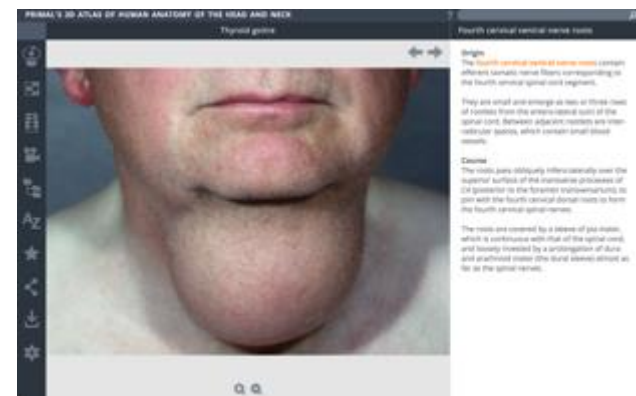
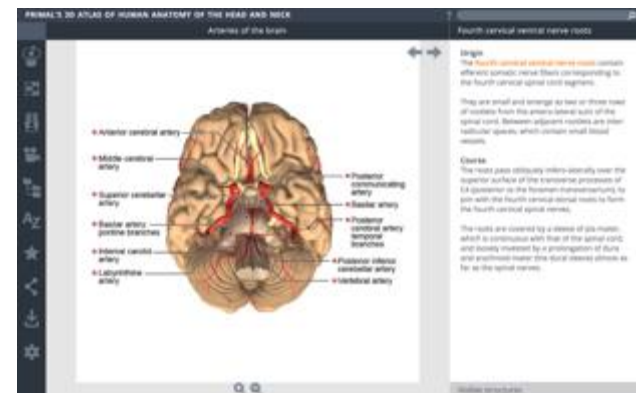
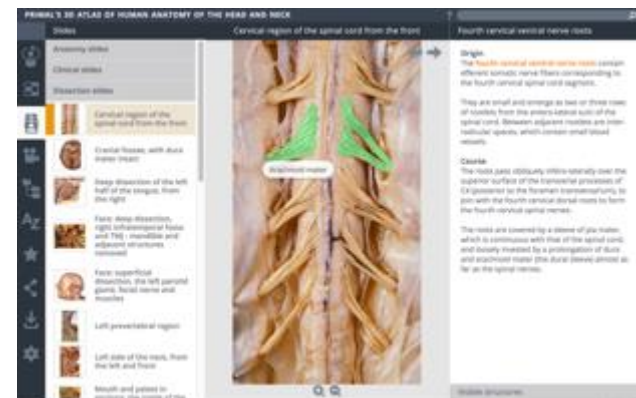
点选左上角的小图标，即可链接至3D
立体图像模式，从另外的角度切入！！

3D Atlas模块使用界面 — 左方功能栏



可以从各分类夹选择查询部位

- 解剖图谱
- 临床与放射科解剖图片
- 大体解剖图片
- 磁共振图像



3D Atlas模块使用界面 — 左方功能栏

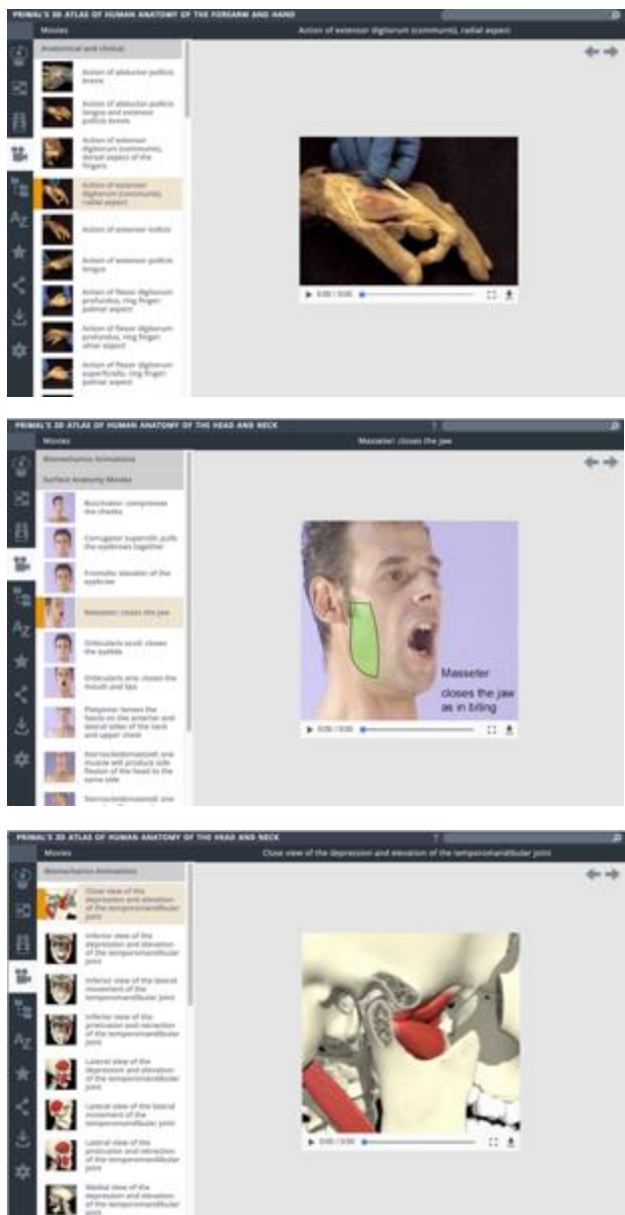Movies

Biomechanics Animations

Surface Anatomy Movies

视频：
依照不同部位模块选择

- 表面动作视频
- 生物动力学视频
- 解剖图
- 骨骼运动视频
- 肌肉功能视频



Anatomical Structures

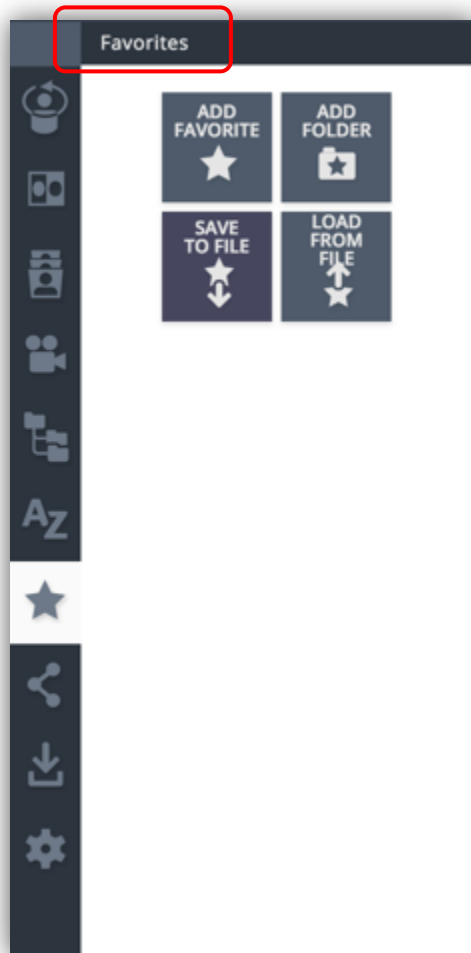
- Alimentary system
- Cardiovascular system
- Connective tissue
- Endocrine system
- Integumentary system
- Lymphatic system
- Muscular system
- Nervous system
- Autonomic system
- Brachial plexus
- Brain
- Cervical plexus
- Cranial nerves
- Cutaneous distribution
- Dermatomes
- Dorsal root ganglia
- Nerve roots

Index

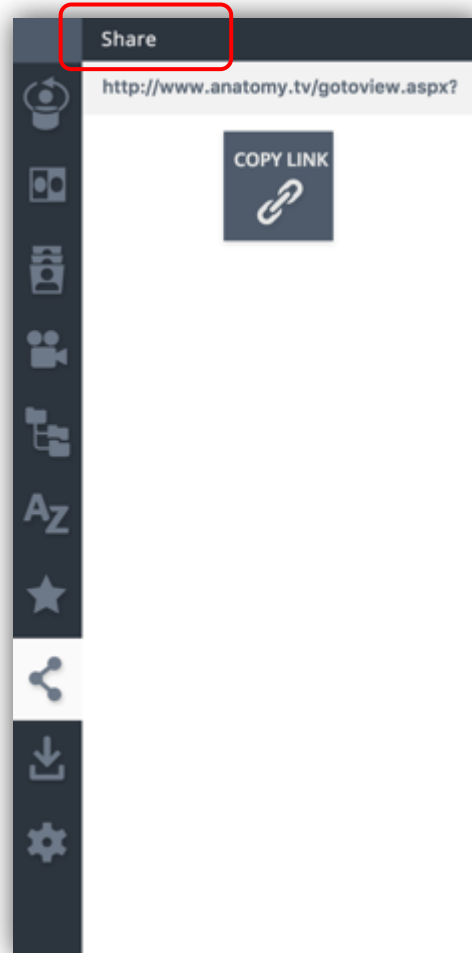
A
B
C
D
E
F
G
H
I
J
K
L
M
N
O
P
Q
R
S

3D Atlas模块使用界面 — 左方功能栏

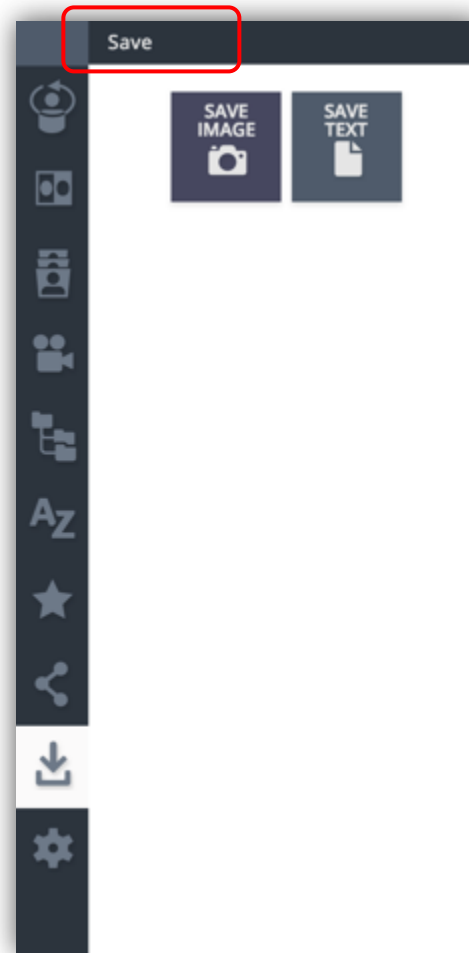我的最爱



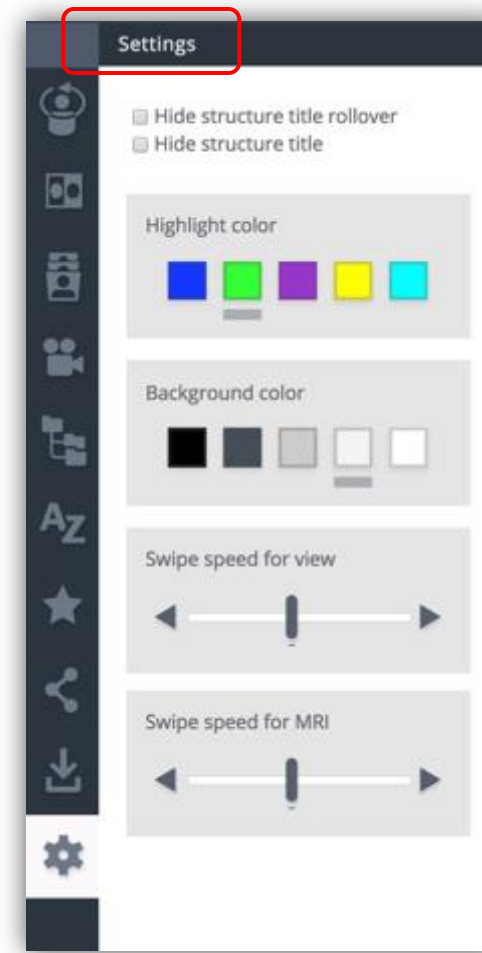
分享链接



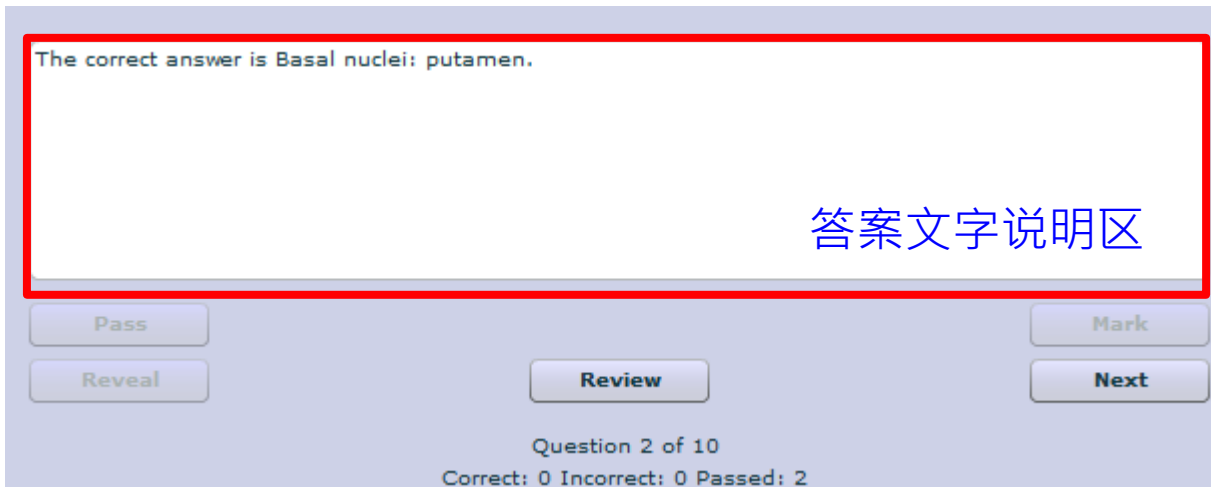
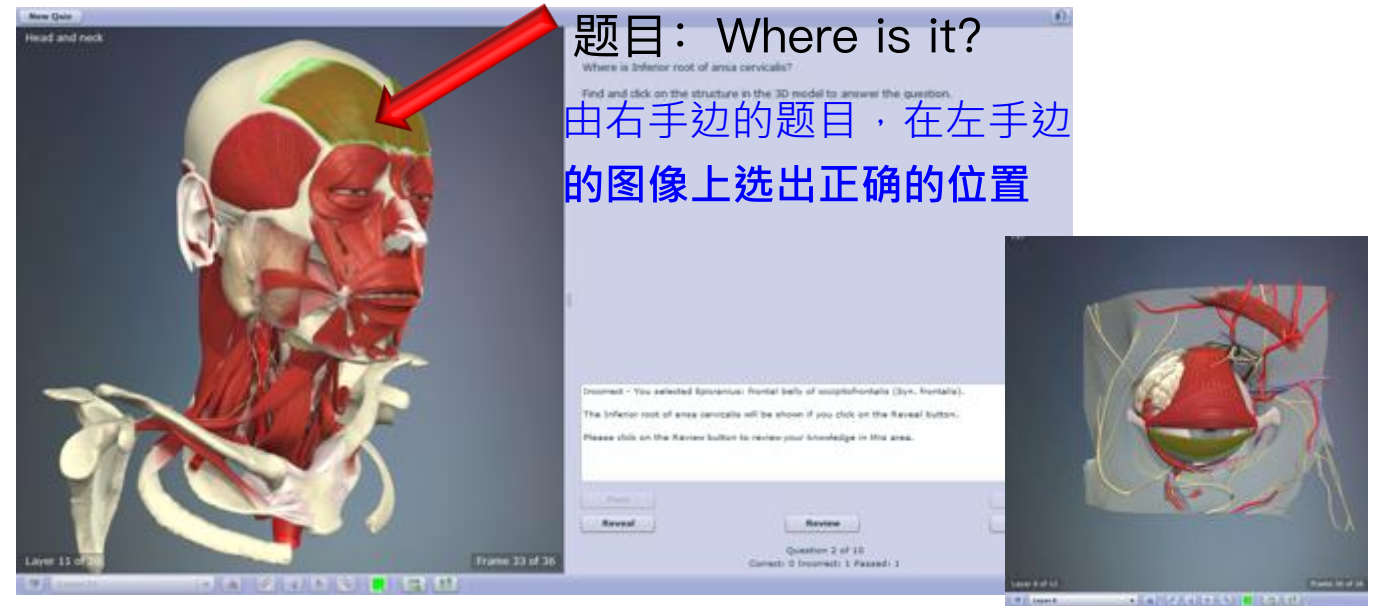
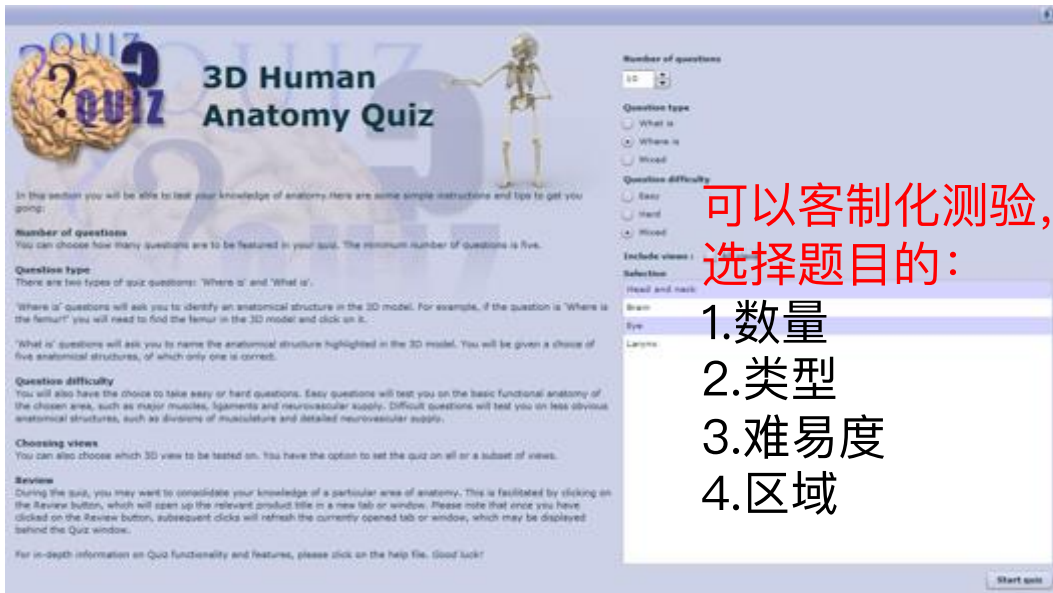
保存图片



设定highlight、背景颜色等

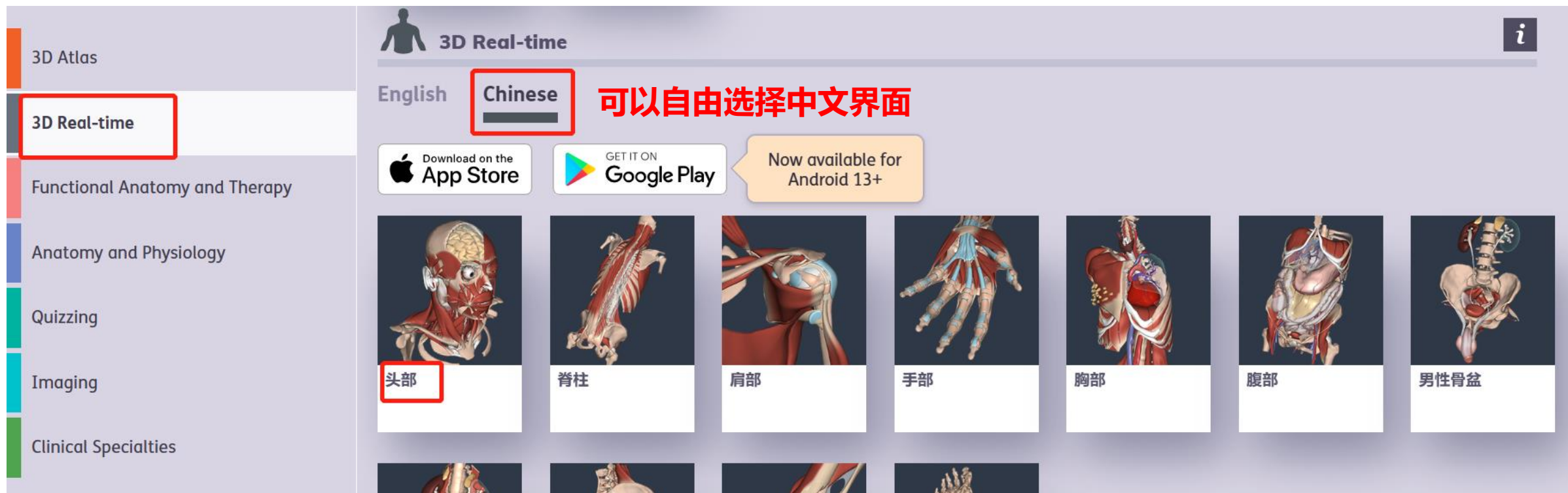


3D Atlas模块使用界面 — Quiz测验功能



按钮	功能
Pass	略过此题目
Reveal	取得答案
Review	连接回Anatomy.tv再次观察
Mark	确认所提取之答案
Next	下一题

3D Real-Time模块使用界面

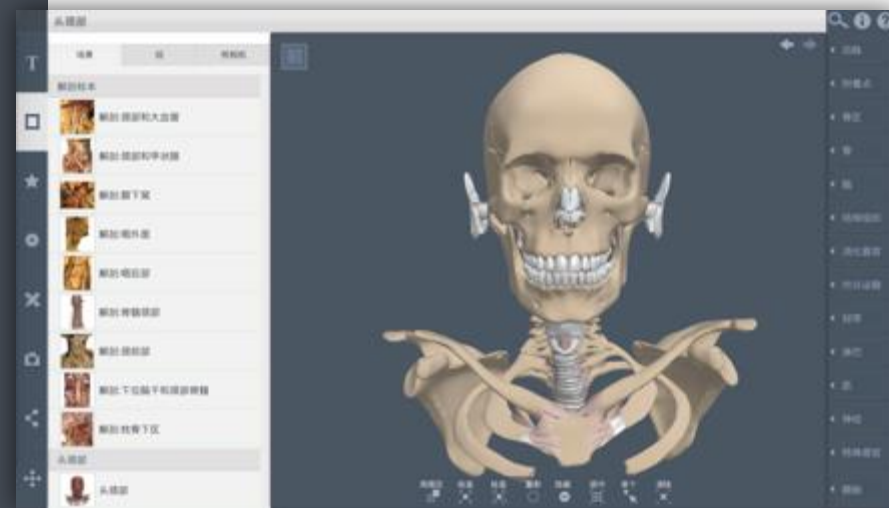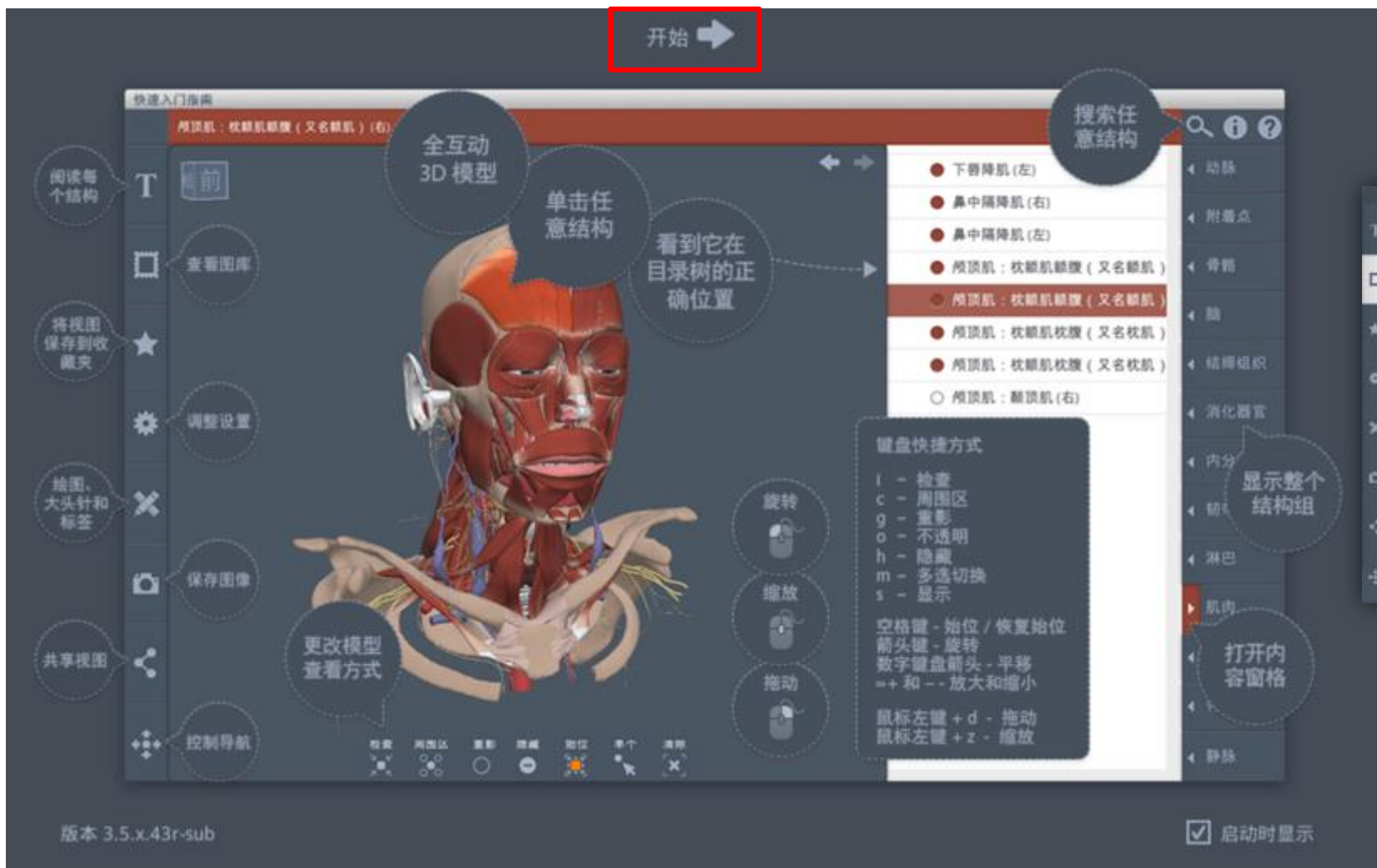


访问网站: <http://www.anatomy.tv/>

以下以头部为范例

3D Real-Time模块使用界面

出现初始画面后，点击开始 (Start)



访问网站: <http://www.anatomy.tv/>

3D Real-Time模块使用界面 — 鼠标操作

The screenshot displays the 3D Real-Time module interface with various control panels. A central white box titled "Rotate, Zoom and Pan on computer" provides instructions for mouse operations:

- Rotate:** 旋转 (Rotate) - 点击并按住左键, 即可将组织360度任意旋转 (Click and hold the left button, you can rotate the structure 360 degrees in any direction).
- Zoom:** 缩放 (Zoom) - 鼠标滚轮向前或向后转动, 即可放大或缩小组织 (Turn the mouse scroll wheel forward or backward, you can enlarge or shrink the structure).
- 移动:** 移动 (Move) - 按住右键, 即可移动组织 (Hold the right button, you can move the structure).

The interface includes several panels:

- Control panels:** Log off - iPad or Android only, Read about structures, View the gallery, Save views as favorites, Adjust the settings, Draw, pin and label, Save images, Share views, Navigation fine control.
- Viewpane controls:** Context, Inspect, Examine, Ghost/Solid, Hide/Show, Home/Home-all, Single/Multi, Clear.
- Contents and Search:** Search for structures, Attachments, Bone regions, Bones, Brain, Connective tissue, Digestive organs, Endocrine glands, Ligaments, Lymph, Muscles, Nerves, Special senses, Veins.

Additional callouts include: "Orientation cube", "Keyboard shortcuts", "Show or Hide groups of structures", and "Open the contents panel".

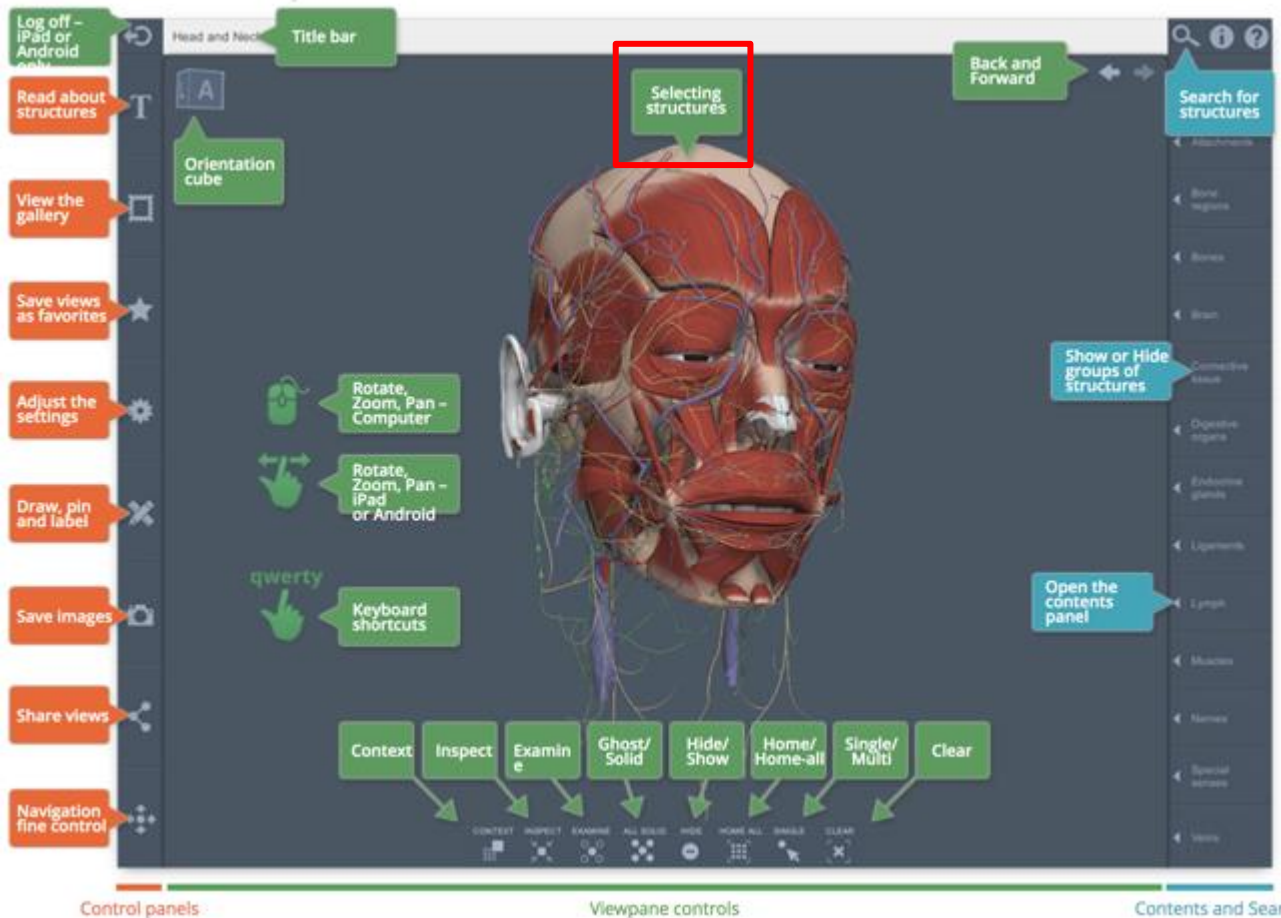
3D Real-Time模块使用界面 - 功能介绍

选择组织:

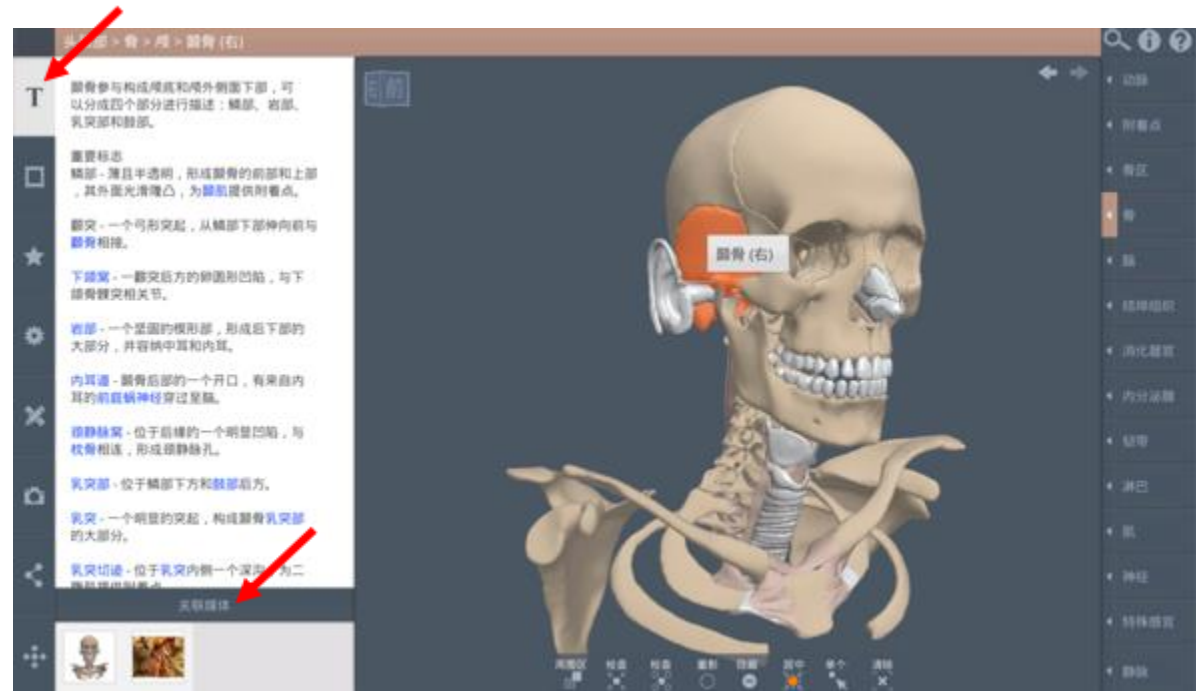
只要将鼠标放在想看的组织并按下**左键**

取消选择:

只要选择其他组织或是**点击背景**的任何地方

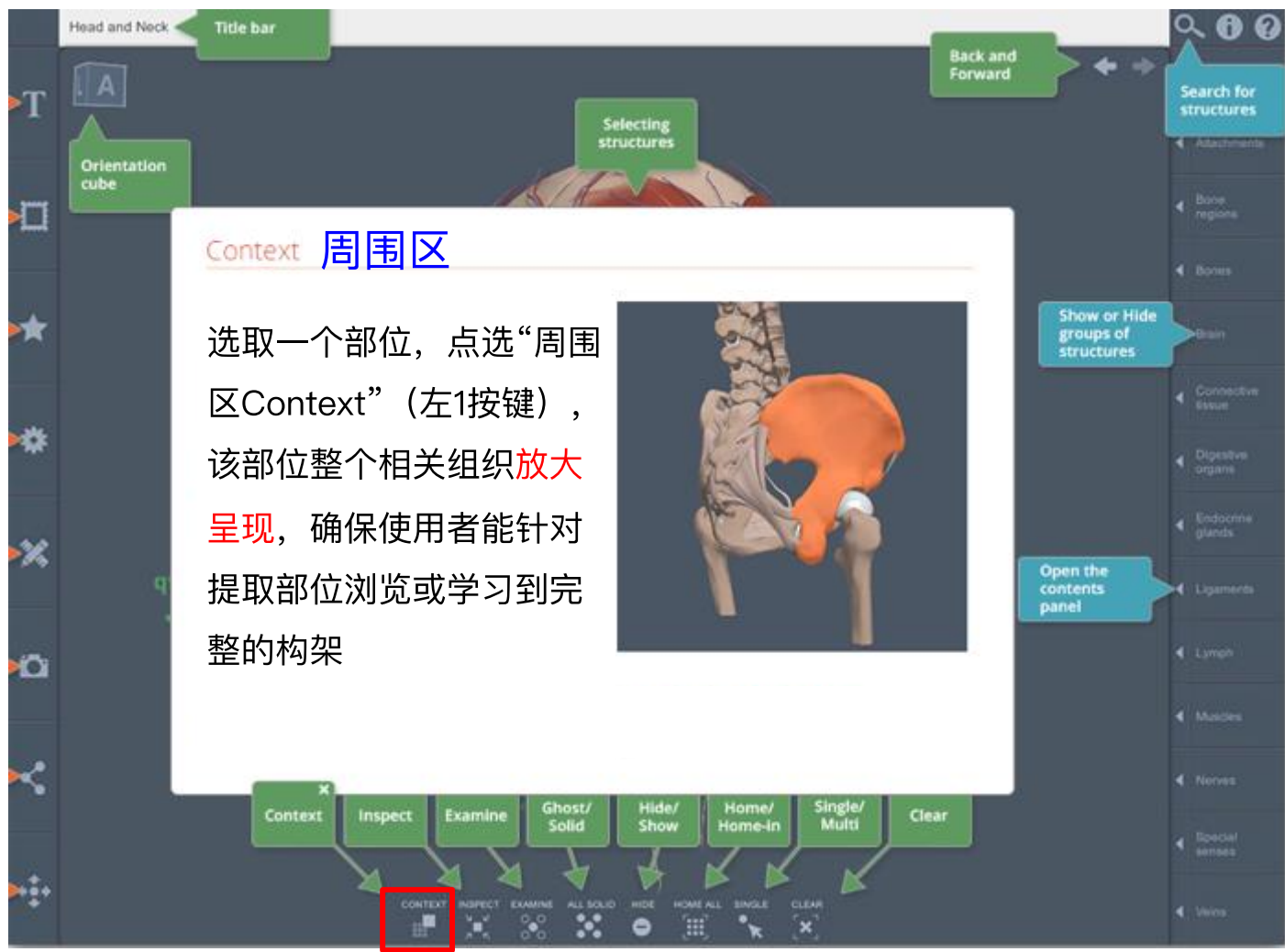

选取组织后，左侧“T”栏位，将有该部位的解释说明

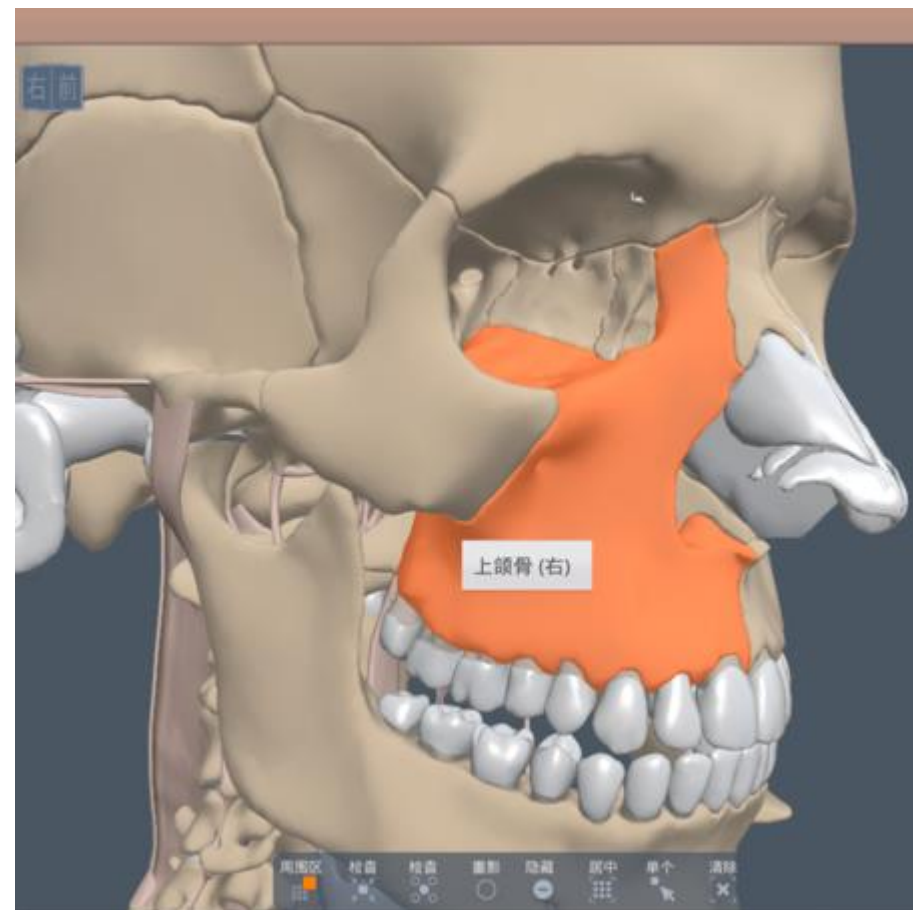


关联媒体中，显示出相关内容，如该部位真实大体图

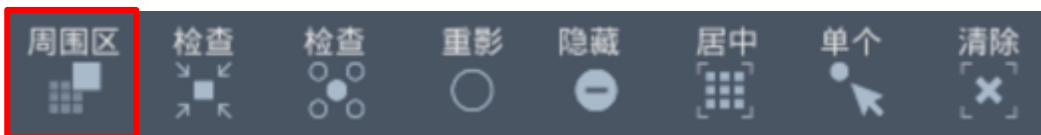3D Real-Time模块使用界面 — 下方浏览操作区



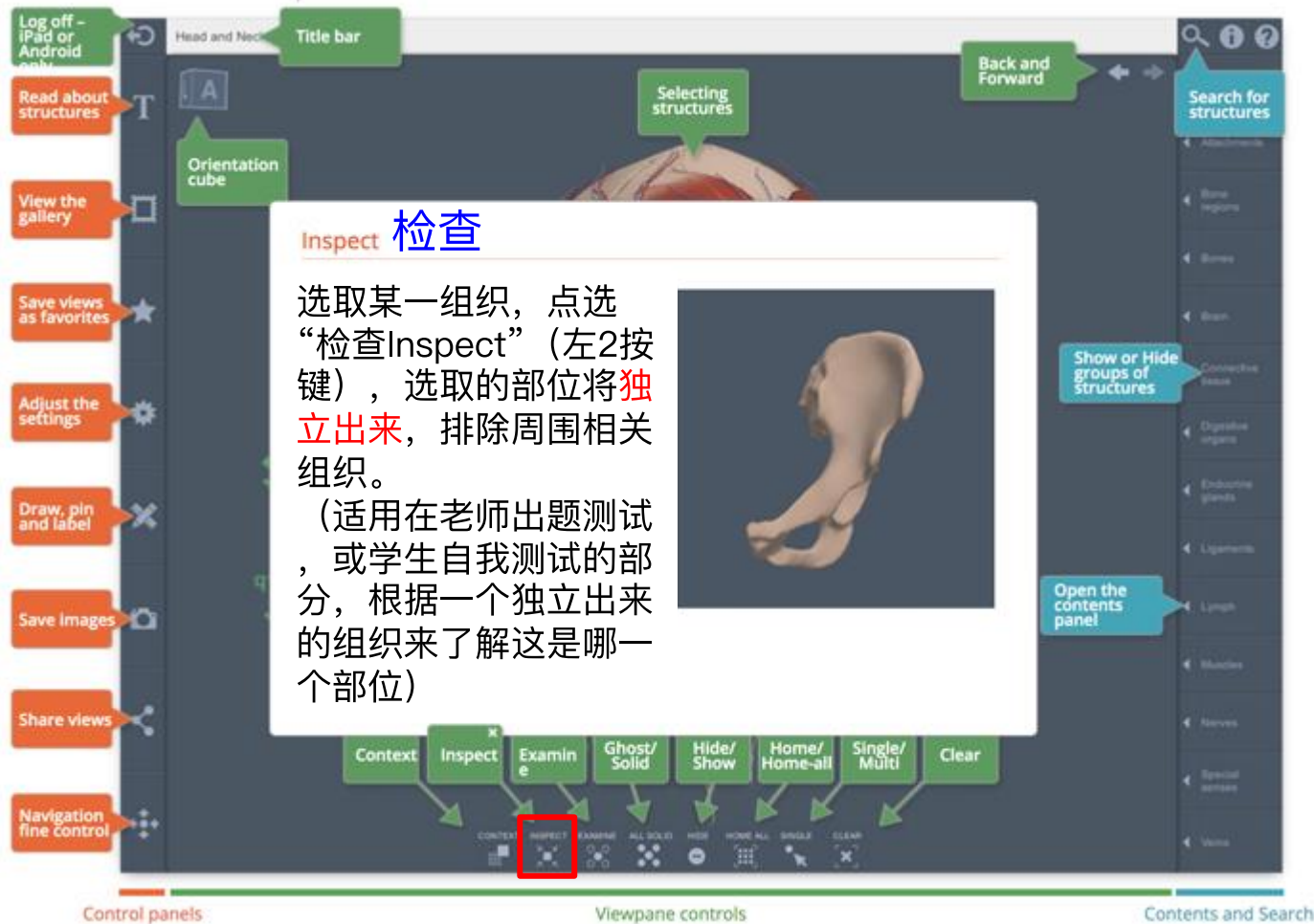
范例：上颌骨（右）



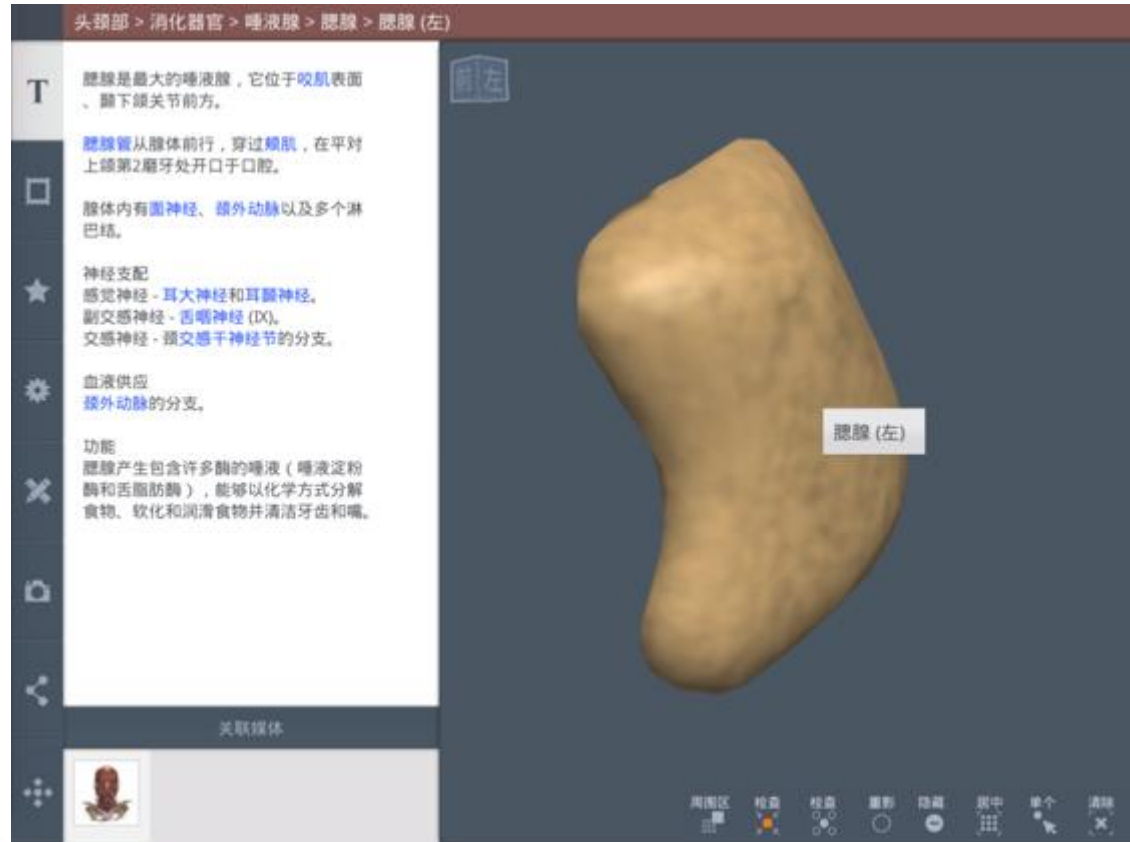中文版：



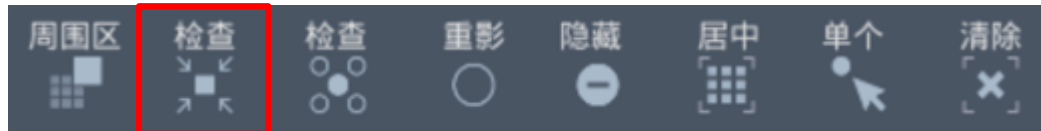3D Real-Time模块使用界面 — 下方浏览操作区



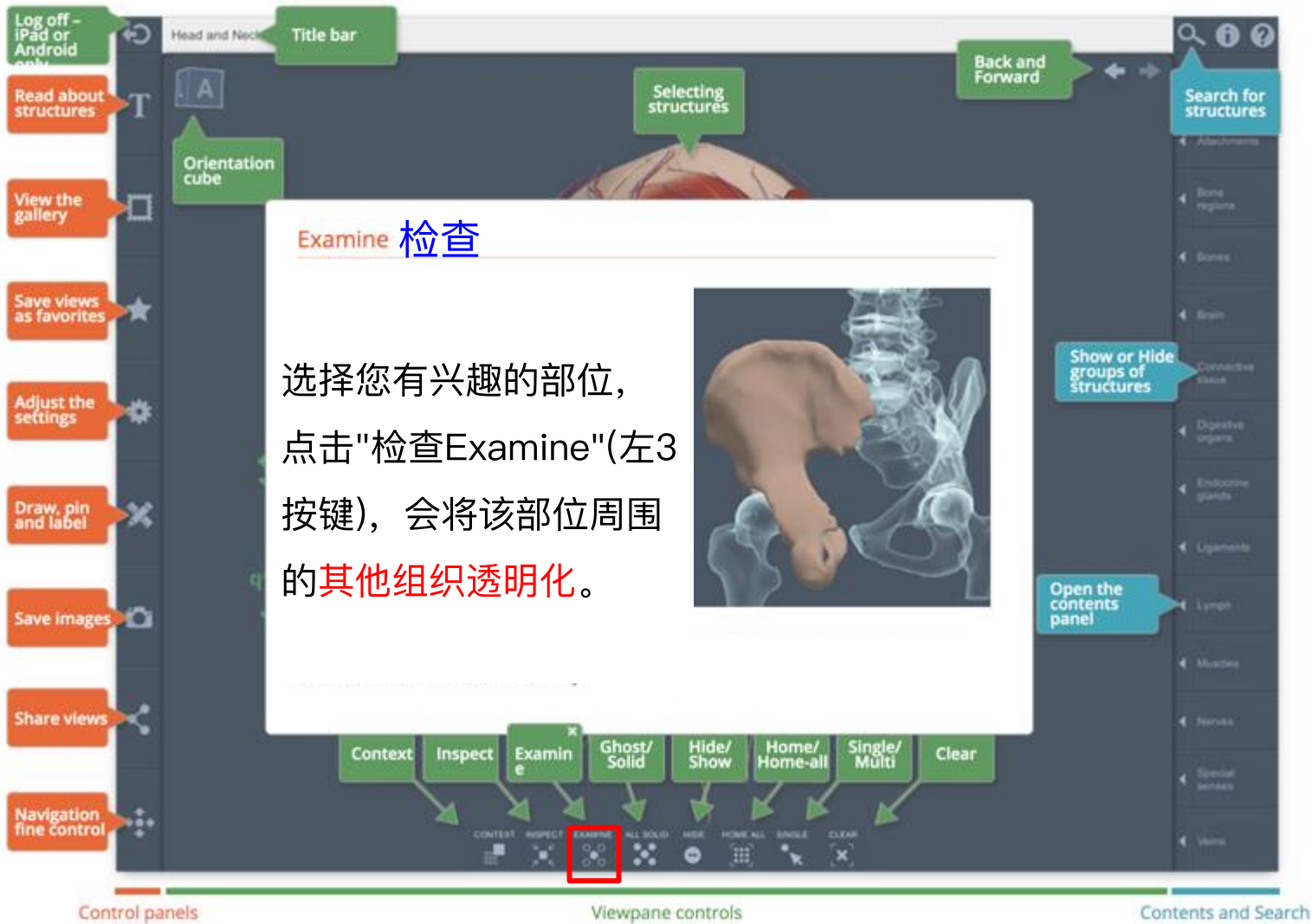范例：腮腺



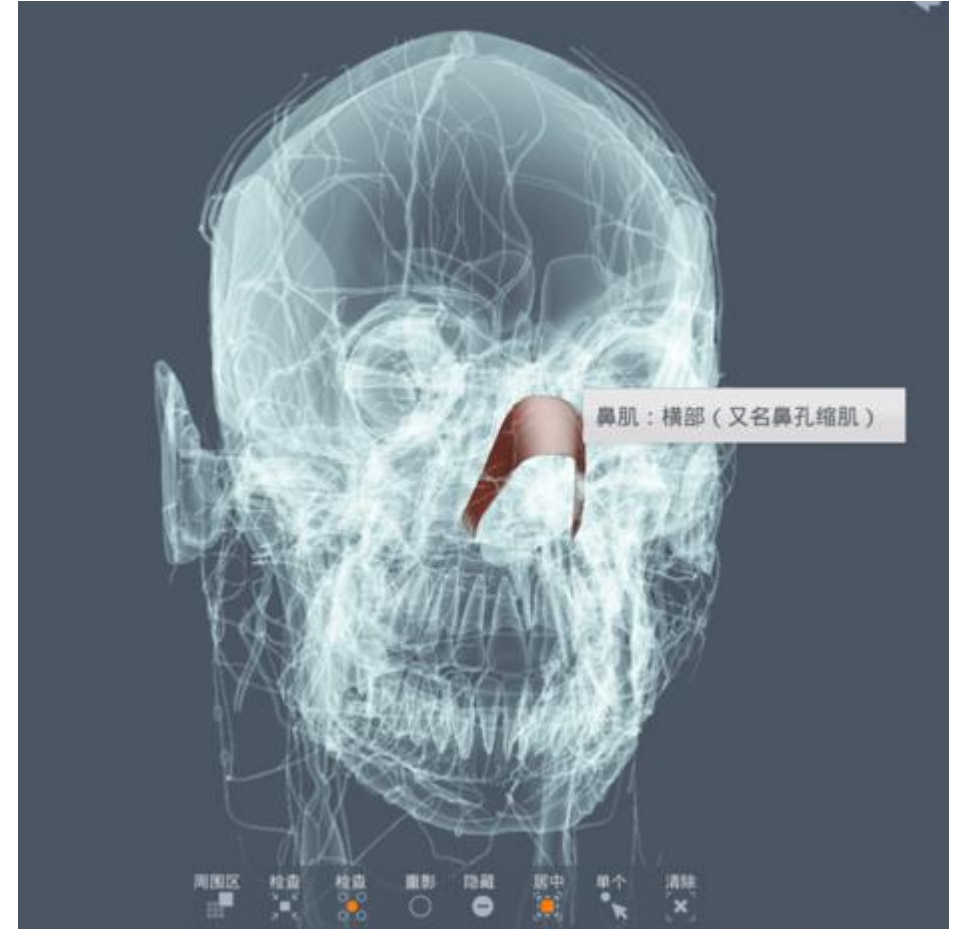
中文版：



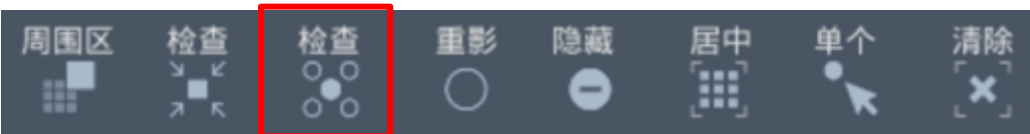3D Real-Time模块使用界面 — 下方浏览操作区



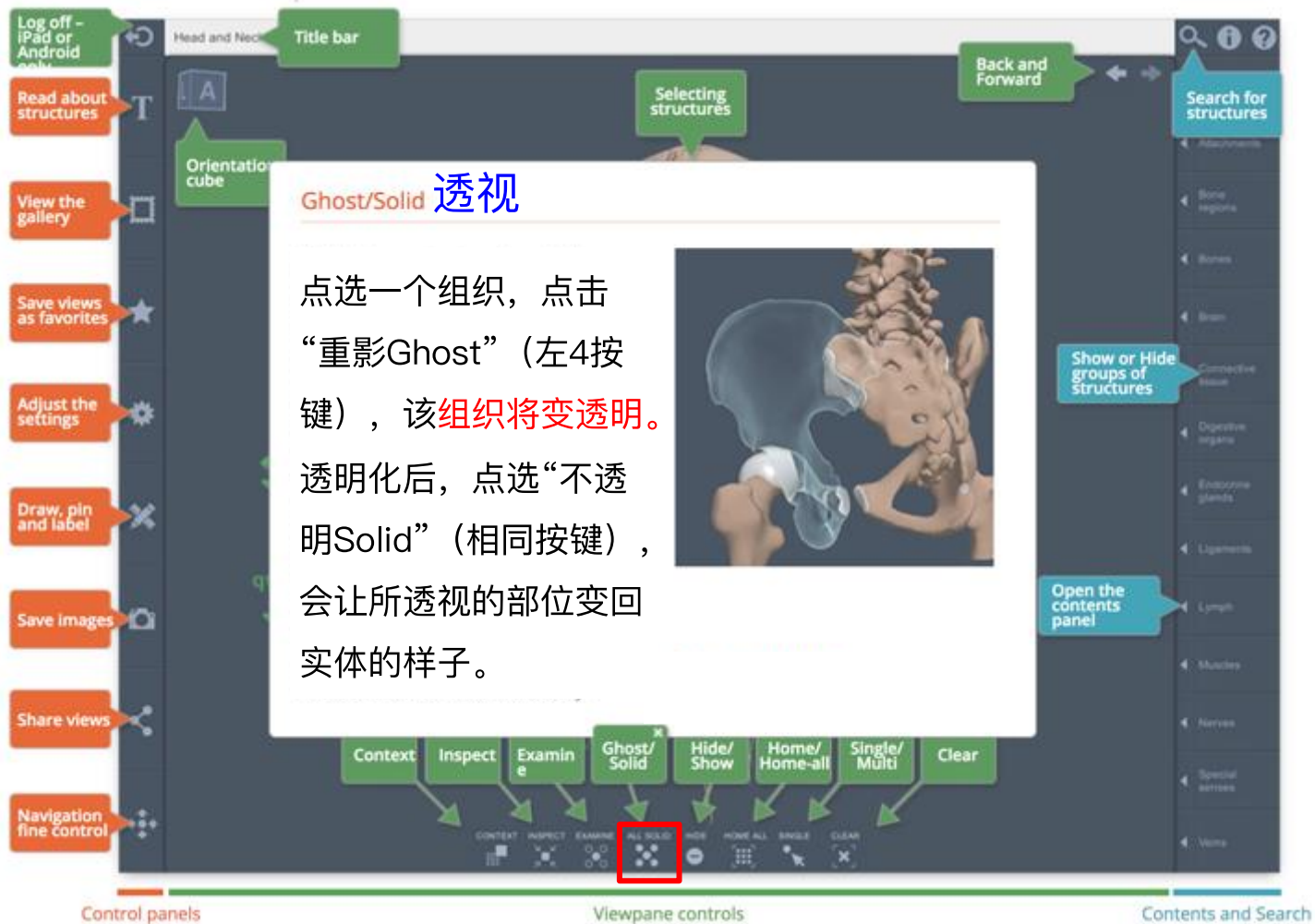
范例：鼻肌



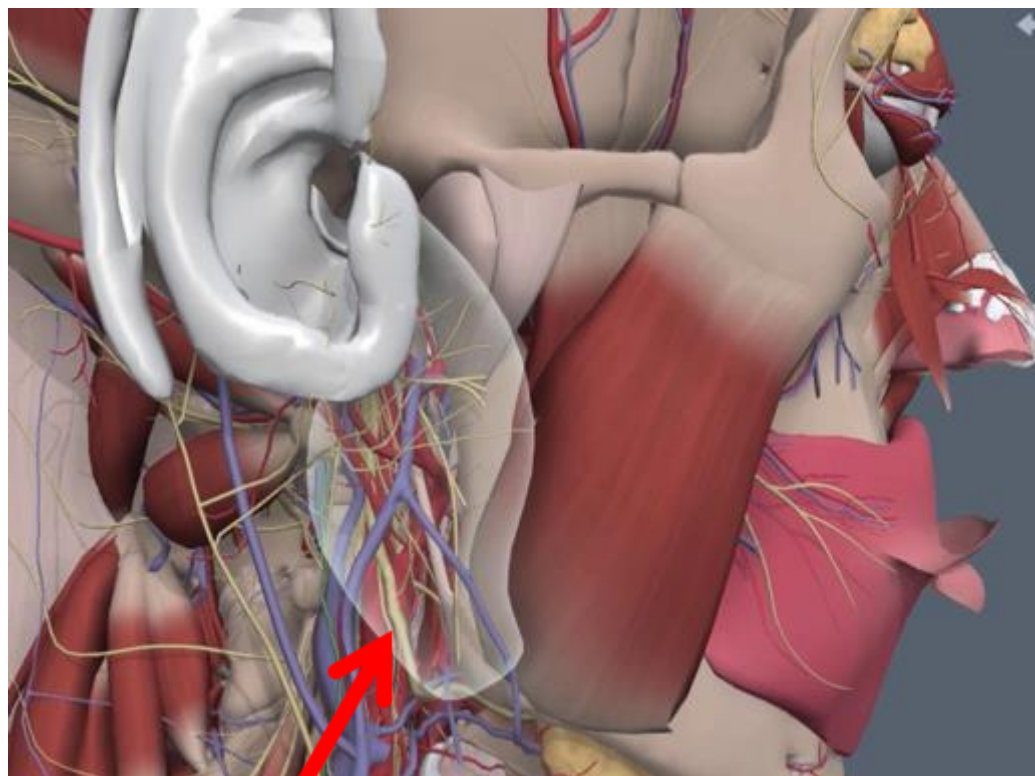
中文版：



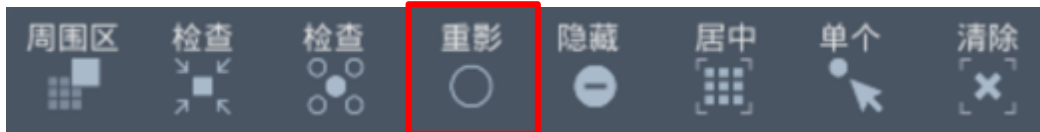3D Real-Time模块使用界面 — 下方浏览操作区



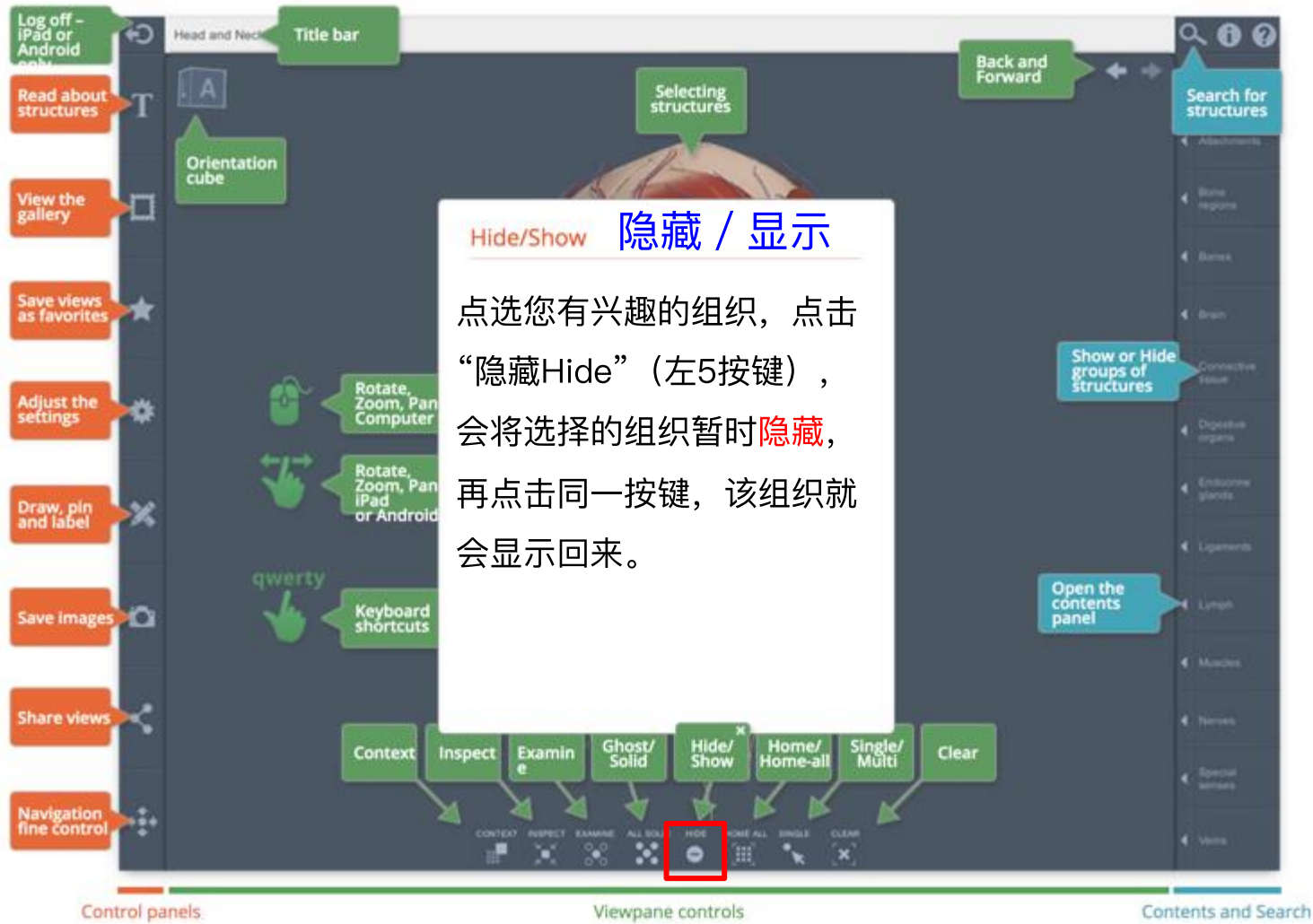范例：将腮腺透明化，观察腮腺底下的组织



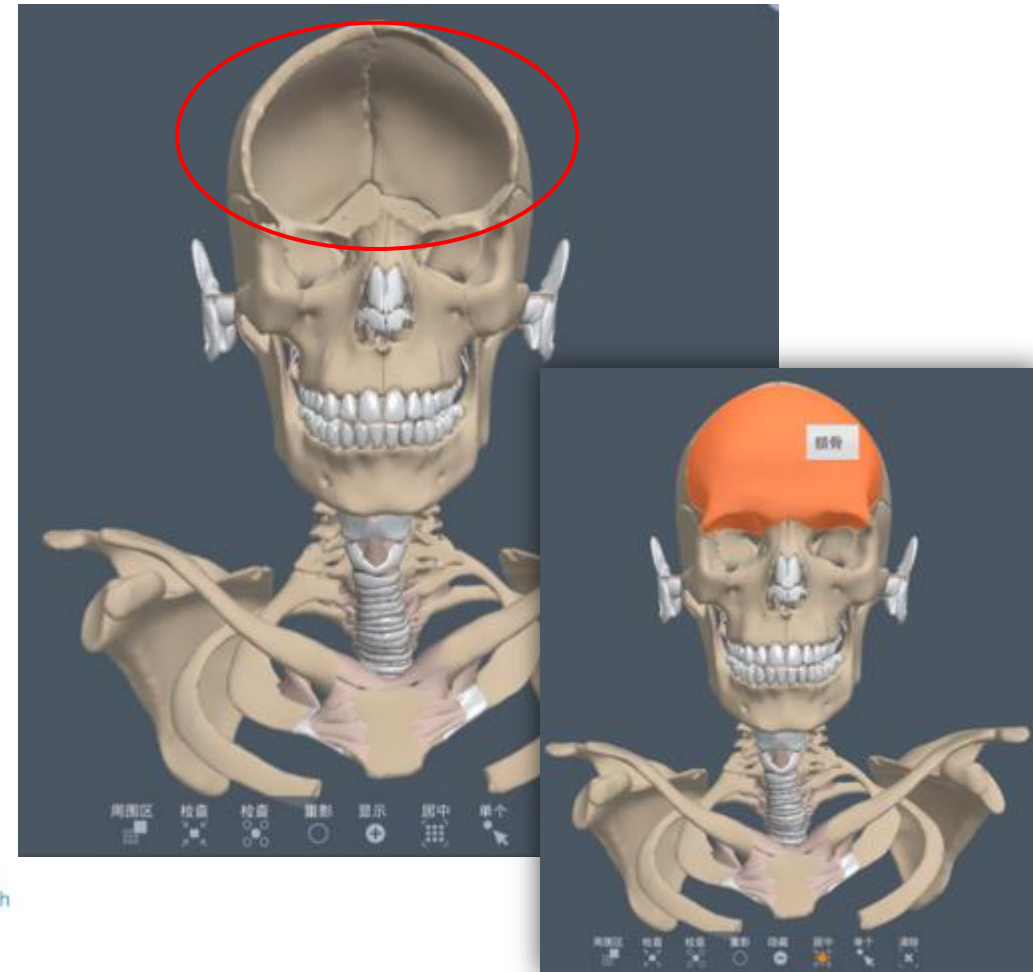中文版：



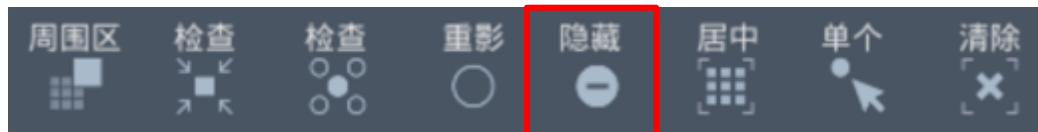3D Real-Time模块使用界面 — 下方浏览操作区



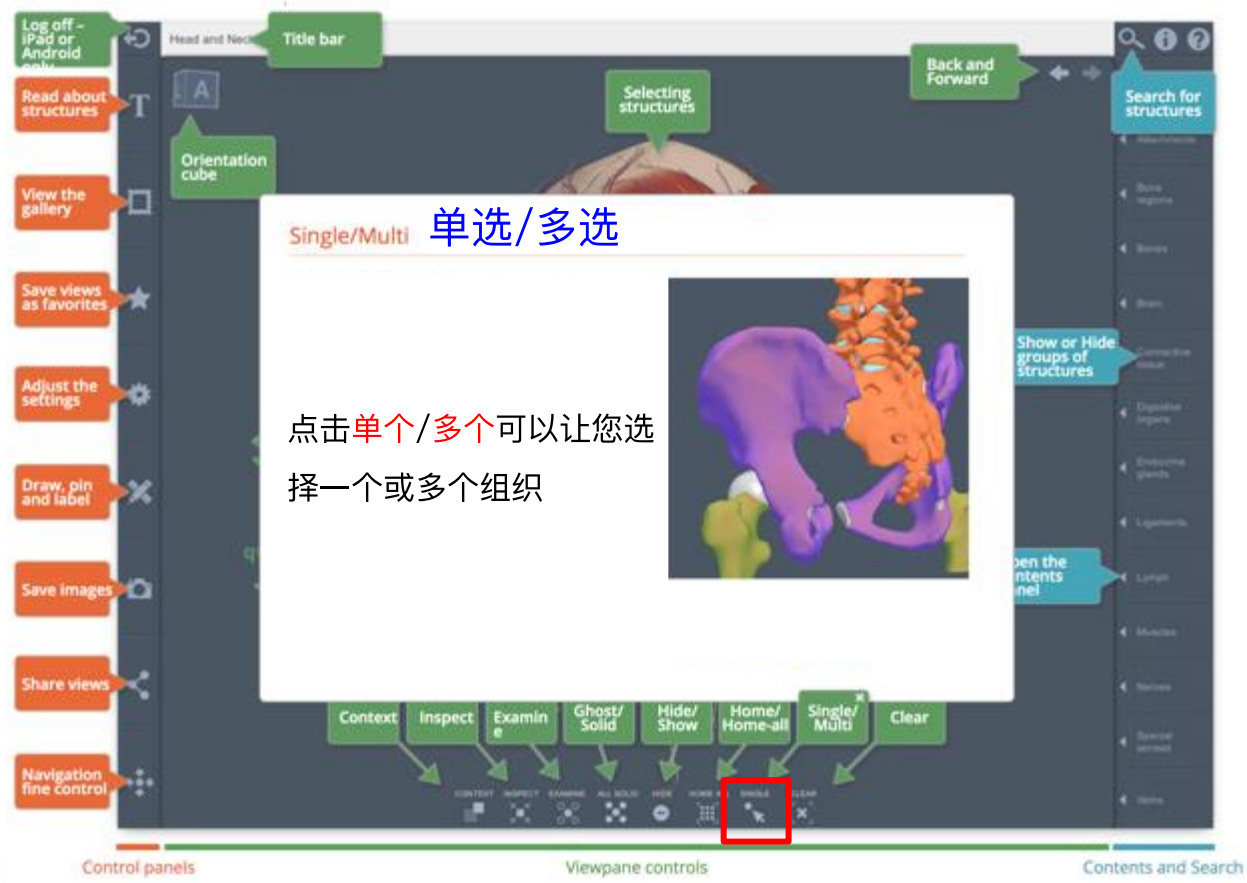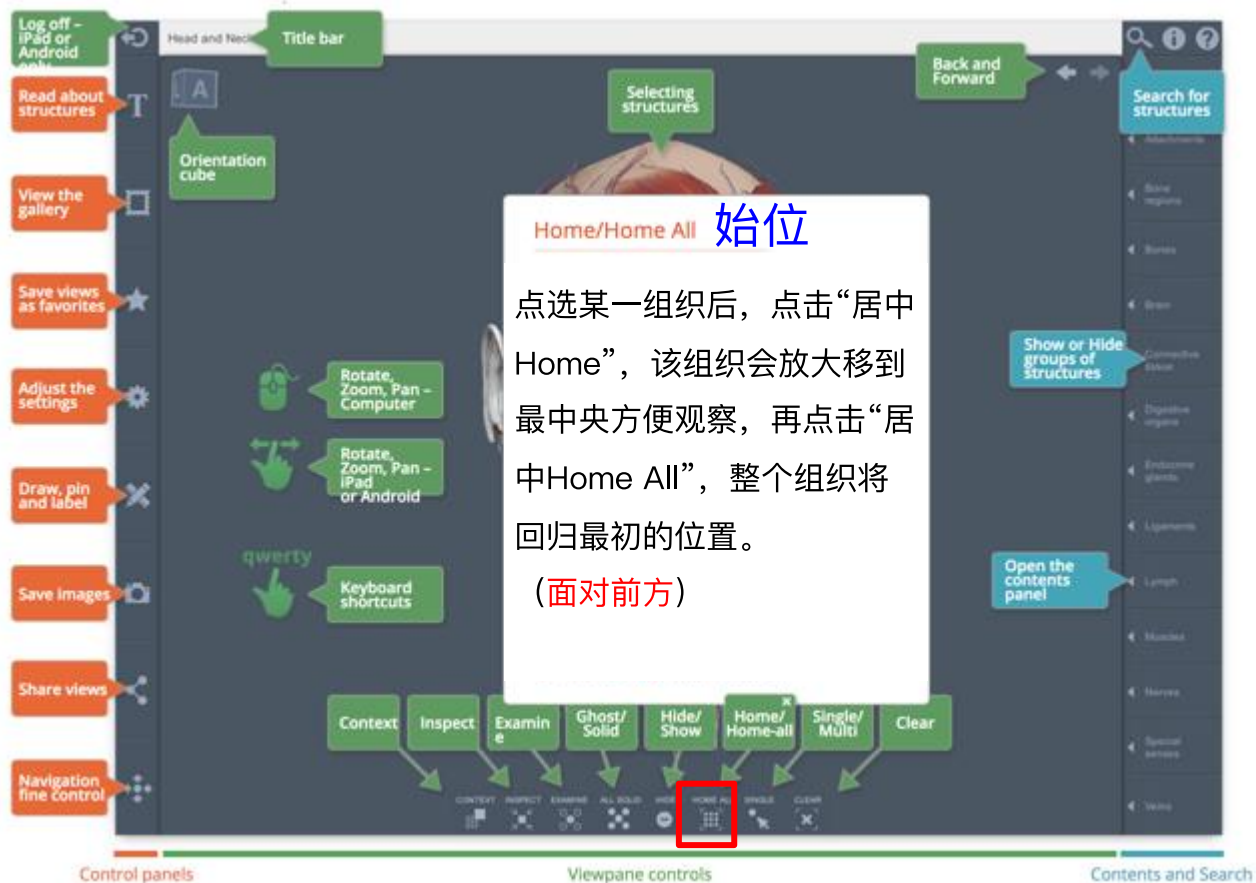
范例：隐藏额骨



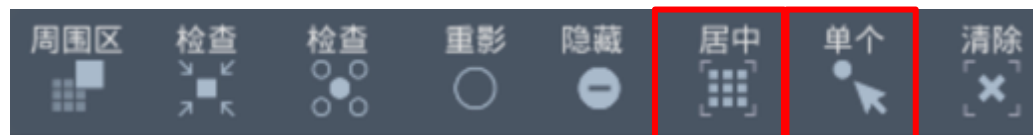中文版：



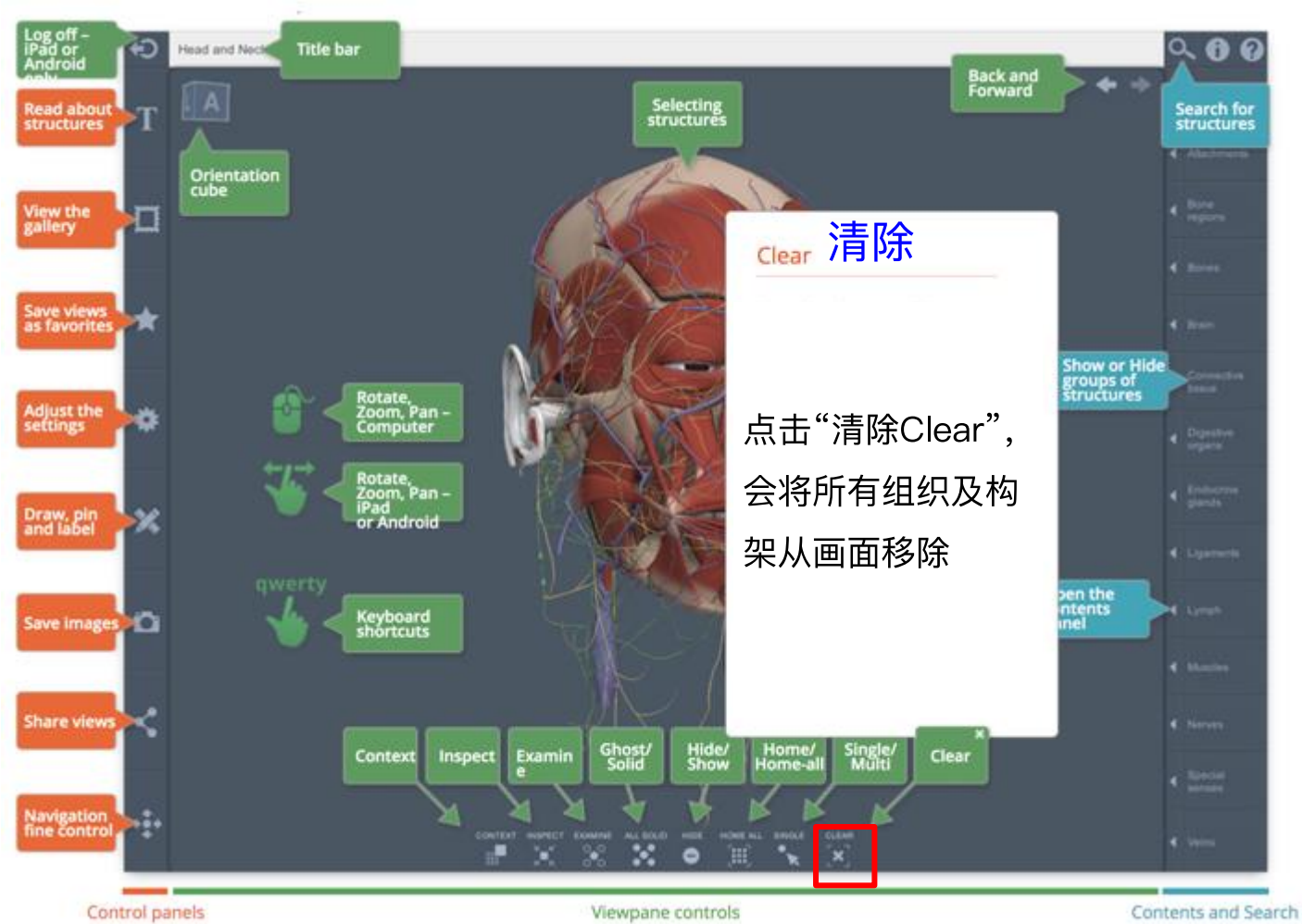3D Real-Time模块使用界面 — 下方浏览操作区



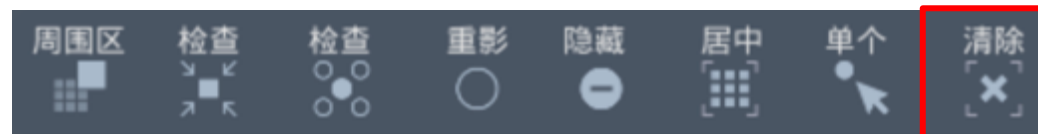中文版:



3D Real-Time模块使用界面 — 下方浏览操作区



中文版:



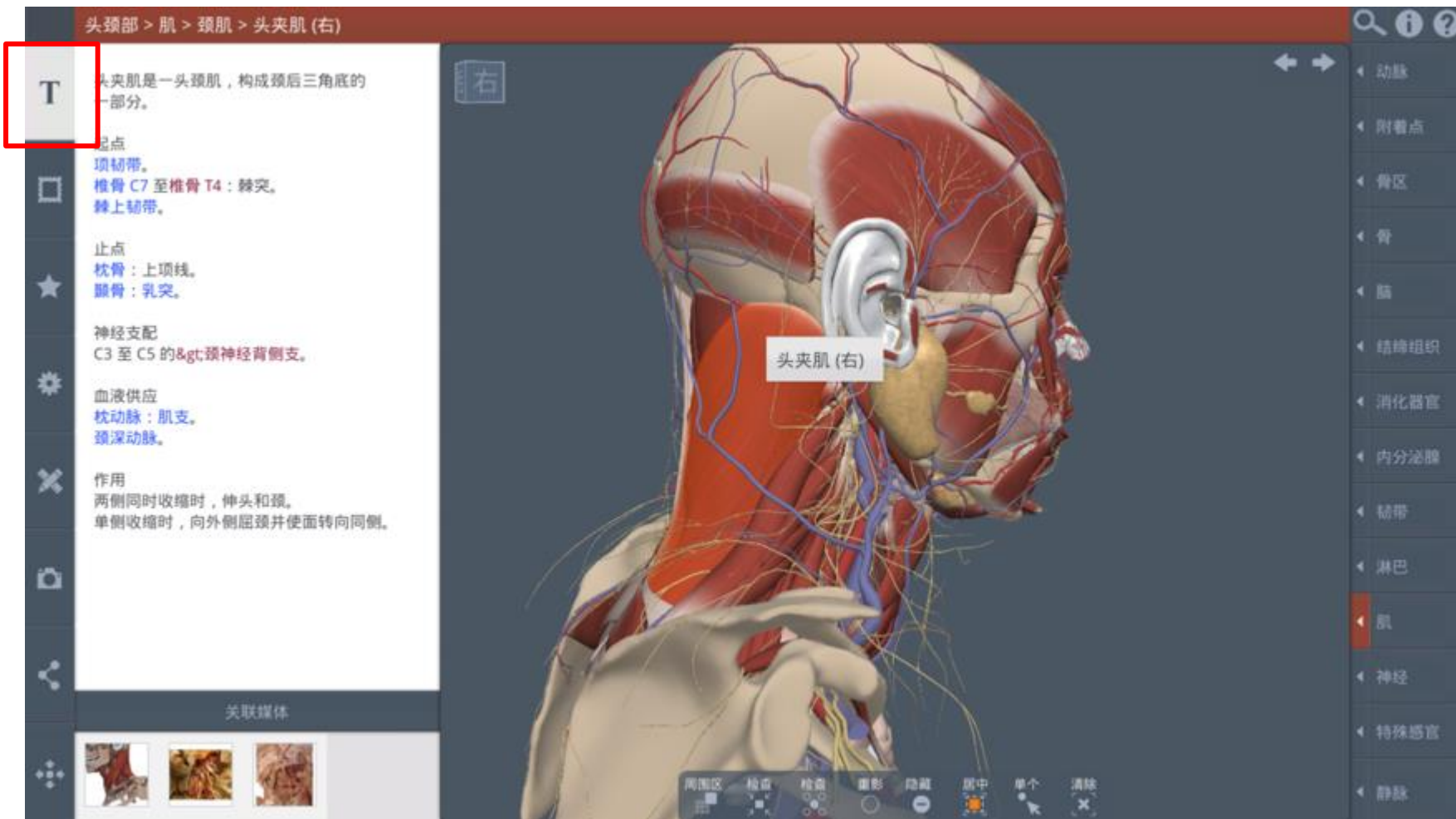
3D Real-Time 模块使用界面 – 左方控制区

Text Display

点选某一组织，点击“T”，会显示所选组织的介绍。

– 介绍中的蓝色字体可以点击，点击后将连接至该组织并显示在画面

– 红色连接表示此组织也出现在其他模块



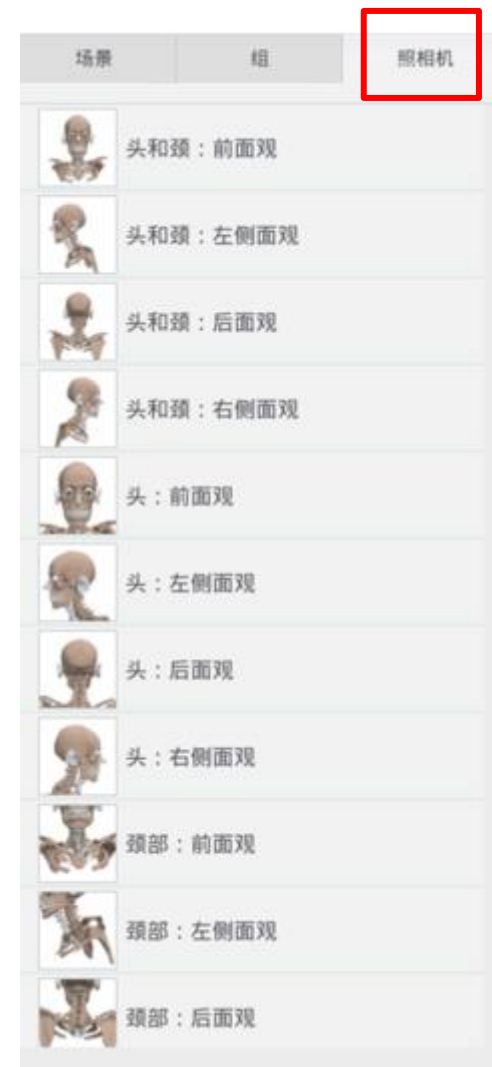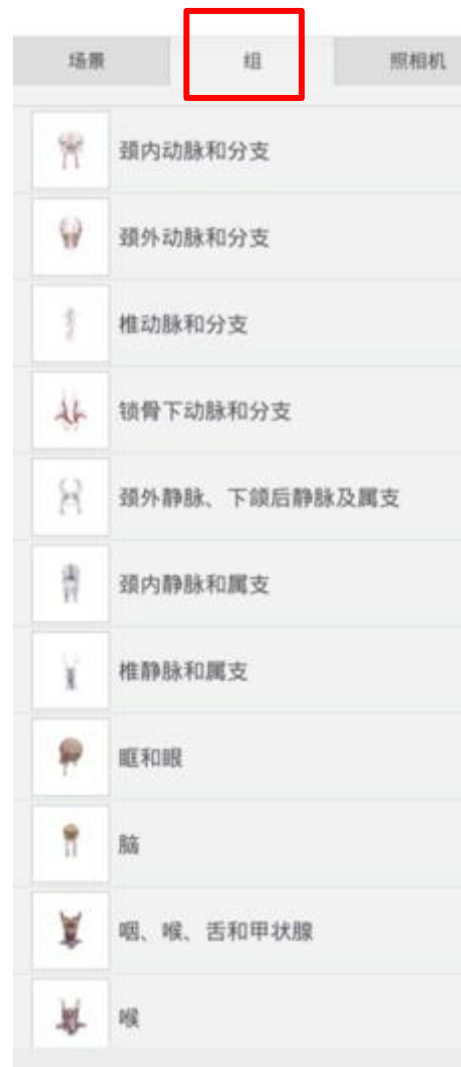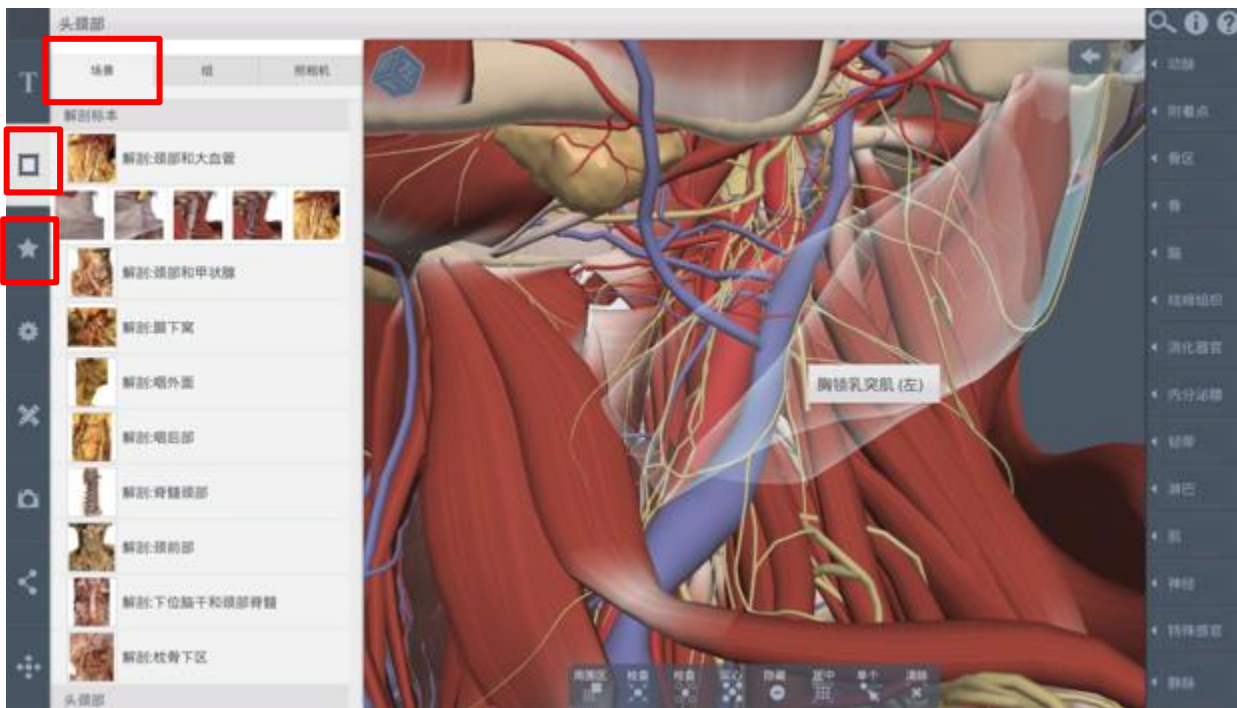
3D Real-Time 模块使用界面 – 左方控制区

- 点击场景 / 组会有**预设好的解剖模块**
- 点击照相机会有**预设好的观看角度**

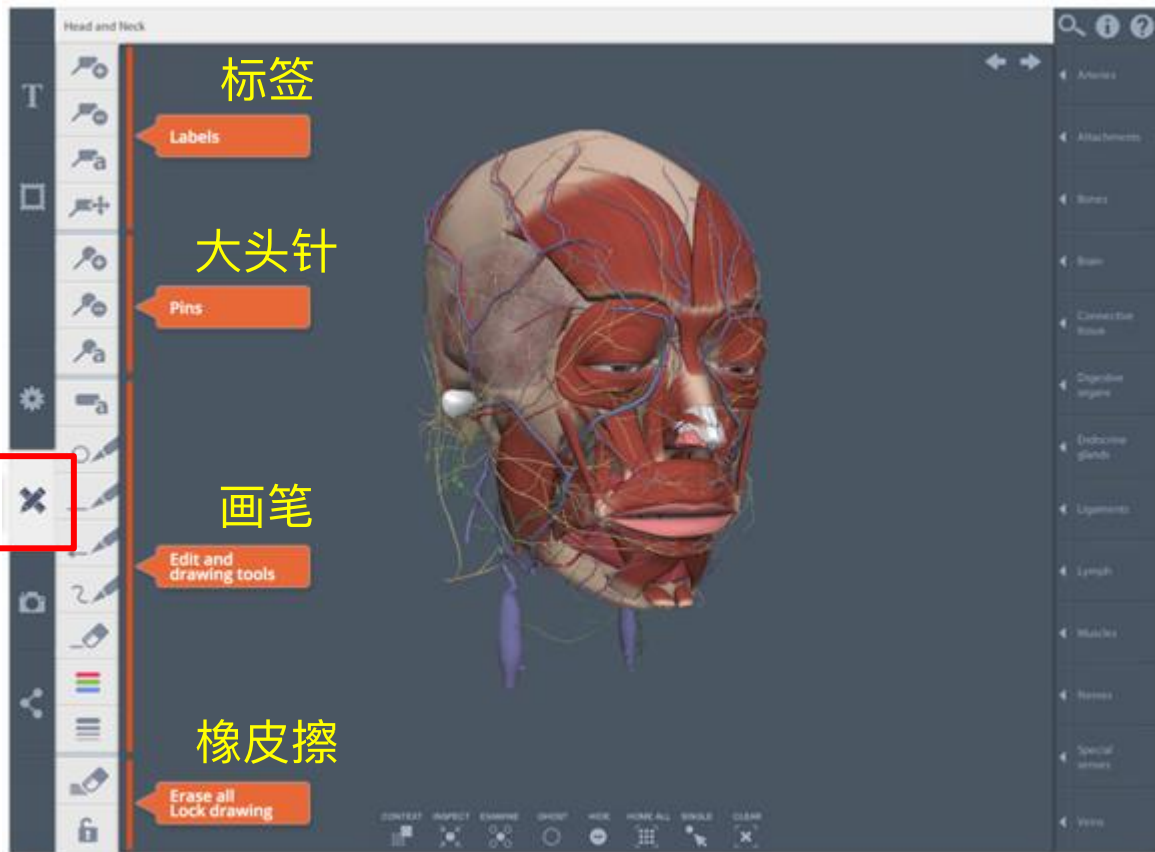
选择场景

我的最爱

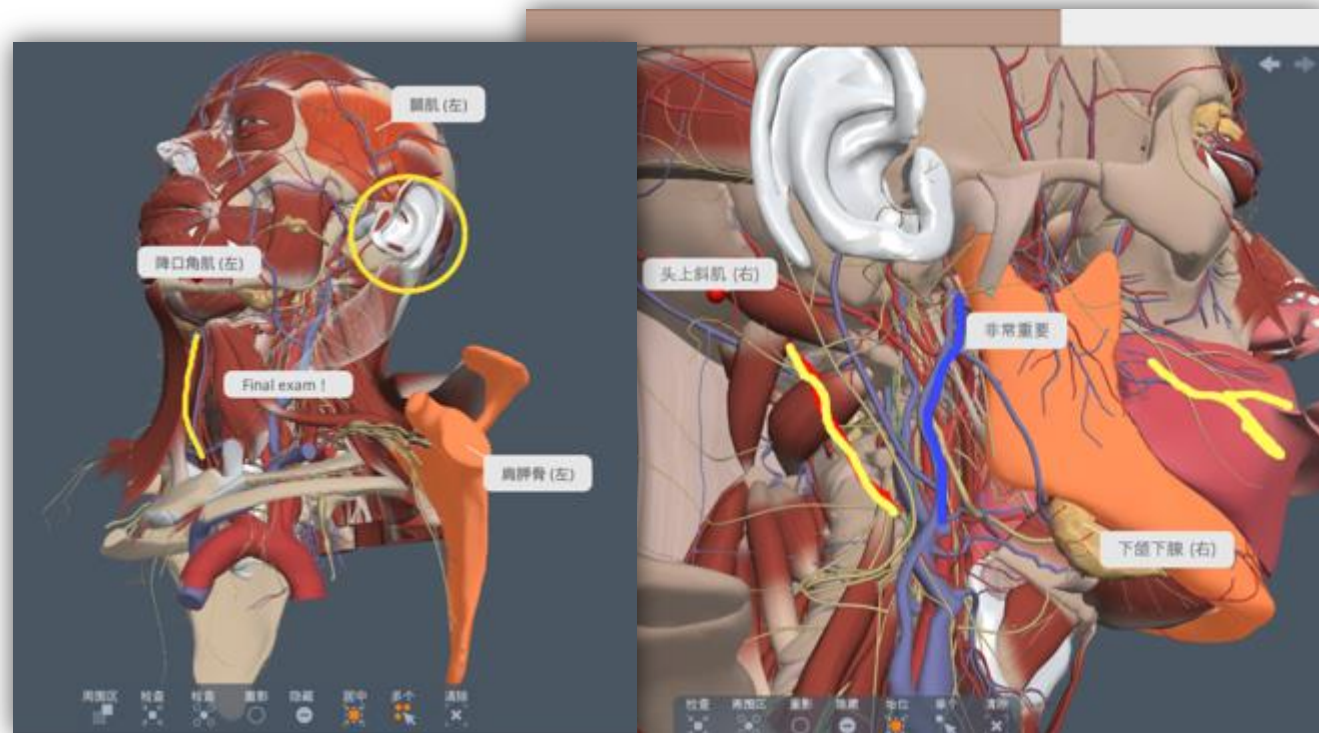
可以将一些自创的场景, 群组跟浏览角度加到我的最爱, 方便日后使用



3D Real-Time 模块使用界面 – 左方控制区



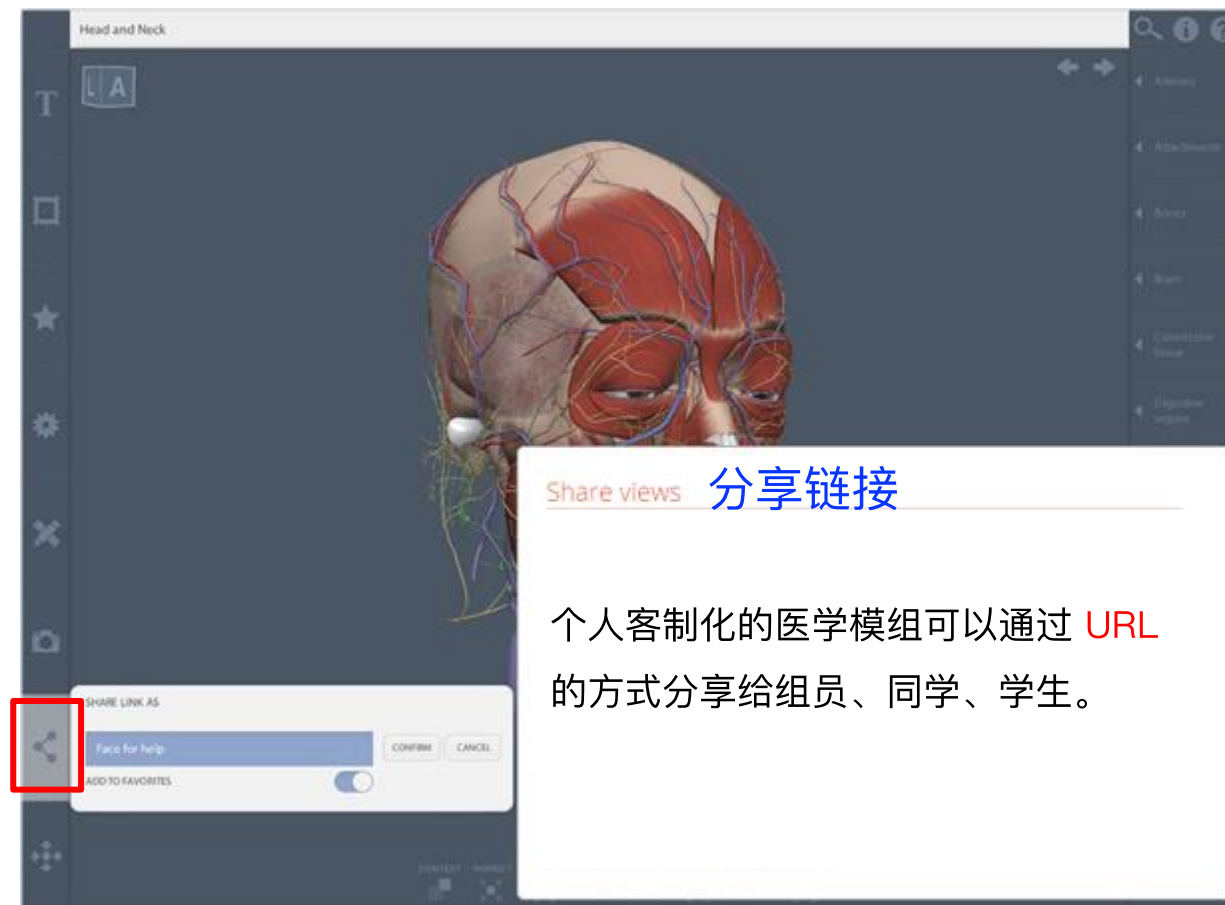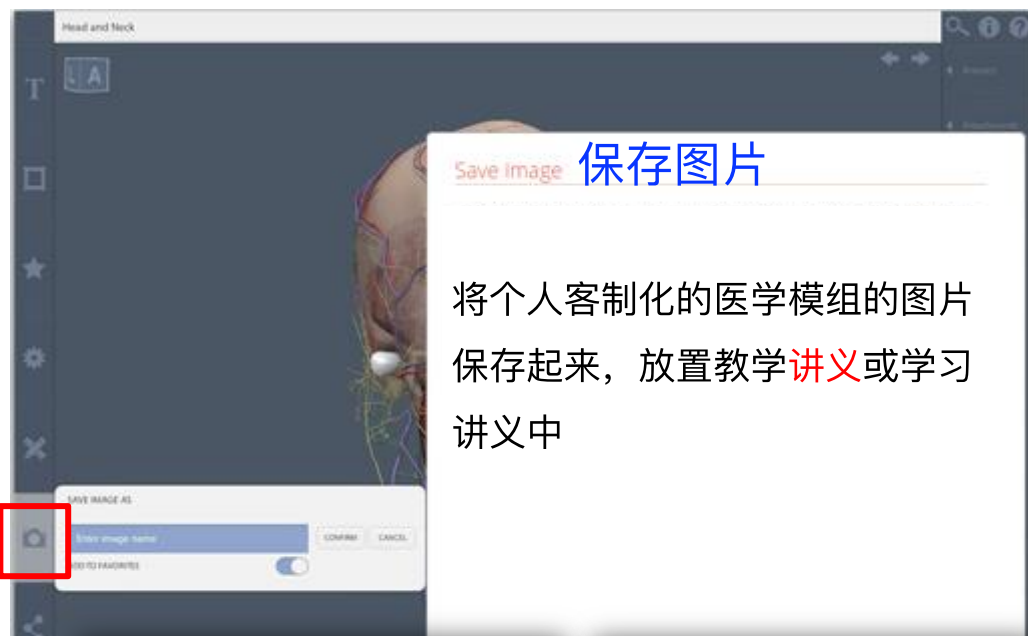
范例:



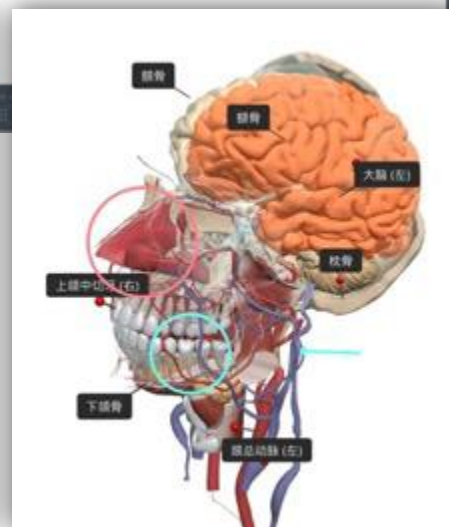
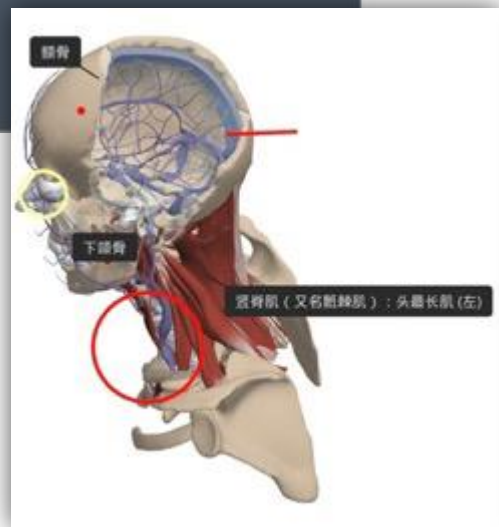
小画家区:

增加标签/大头针/备注以作笔记

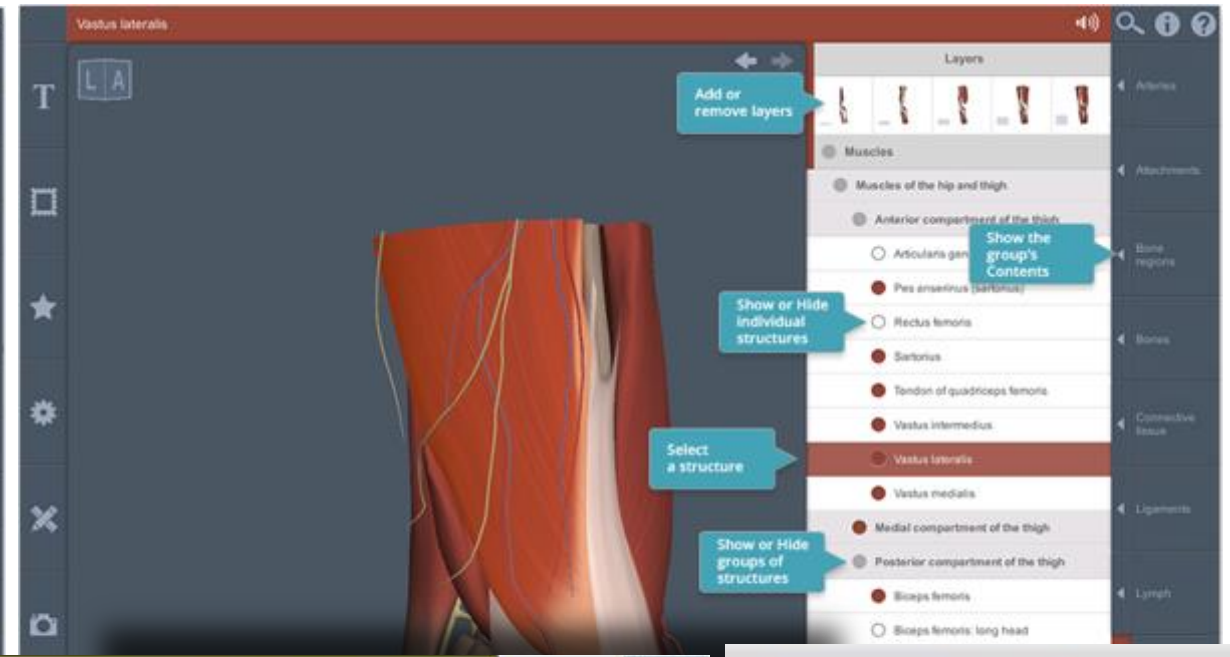
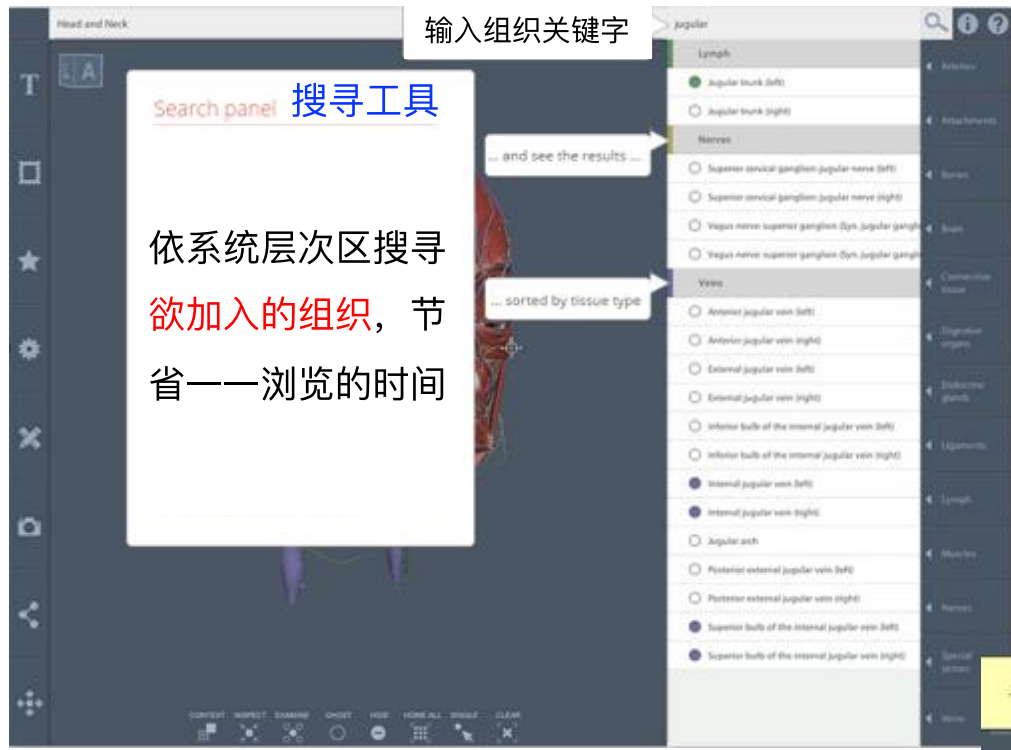3D Real-Time 模块使用界面 – 左方控制区



范例：



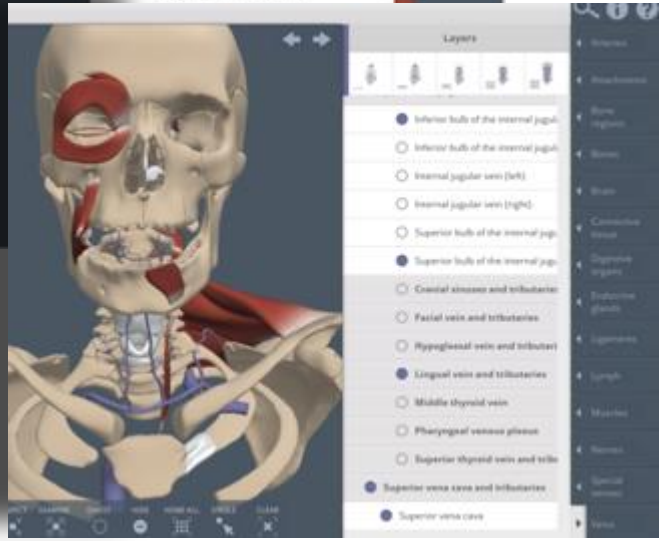
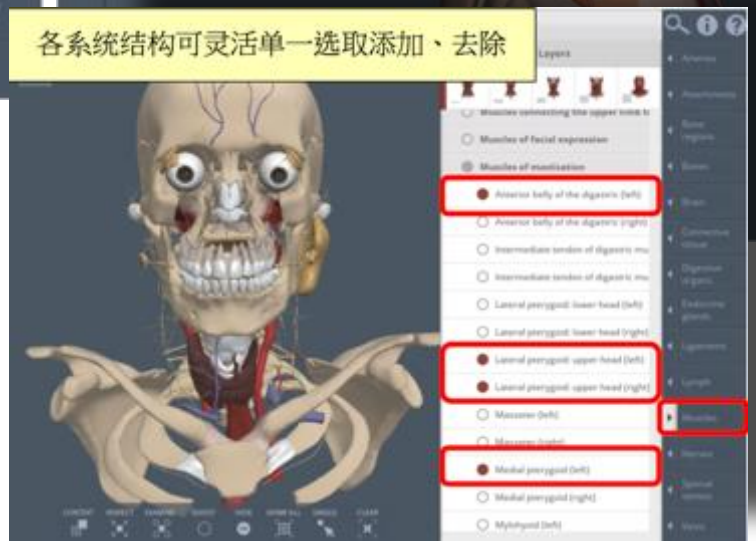3D Real-Time模块使用界面 — 右方组织系统及搜索区



阶级系统选择区

选择增加或移除的系统层次，选择欲增加或移出组织内容

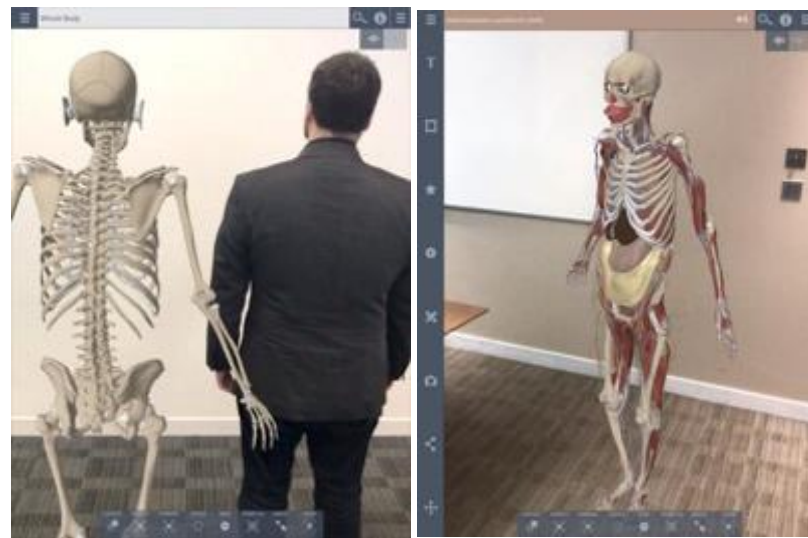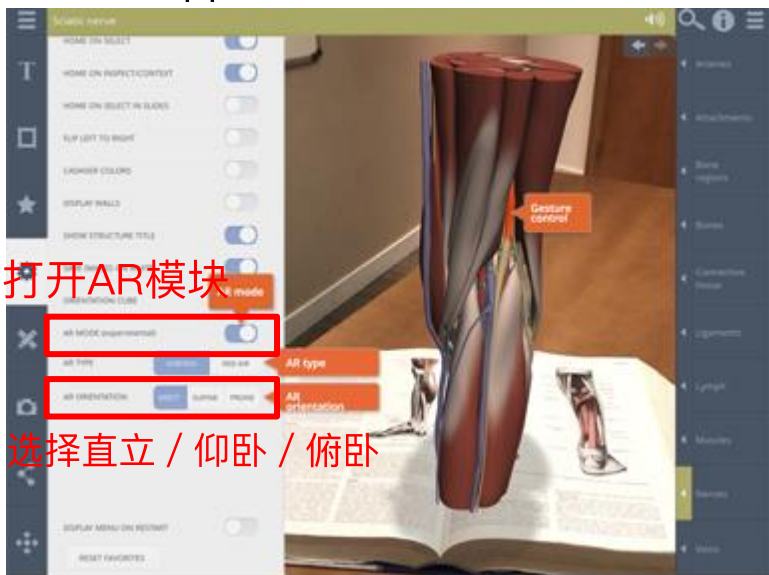该功能可以高度客制化医学模组！



3D Real-Time模块 — 行动App（操作方式都与电脑版相同哦）

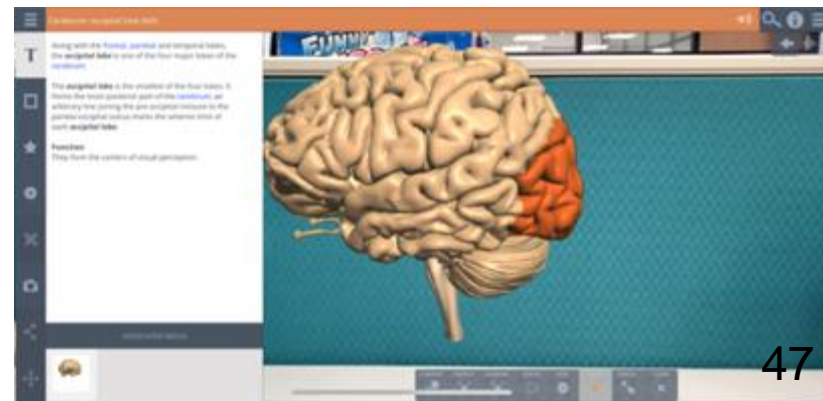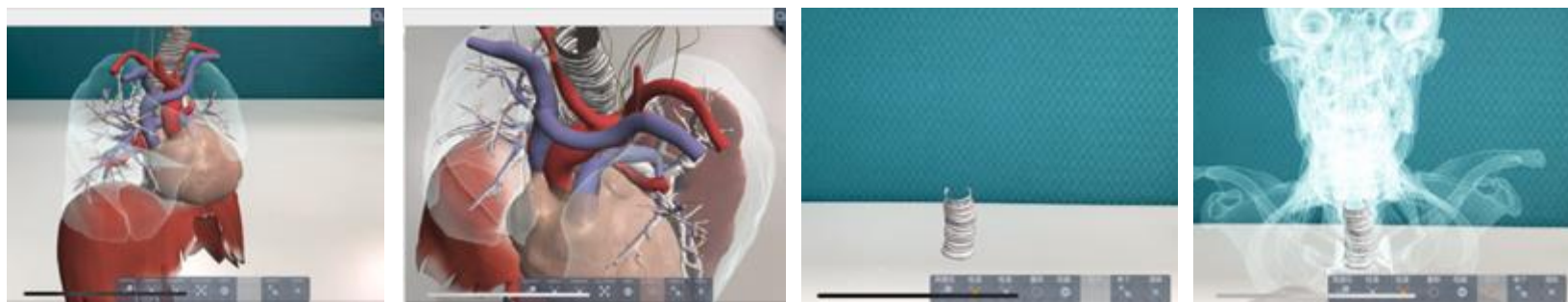
需先将手机、平板连线至贵单位Wi-Fi（IP范围），至App下载程式搜索 **Primal Pictures Ltd** 进行下载。
下载完成以后，用自己的行动网络或Wi-Fi就可以在校内外使用了哦！（备注：若为试用期间，即可直接用账号密码登入）

■ 手机App独有AR扩增实境功能



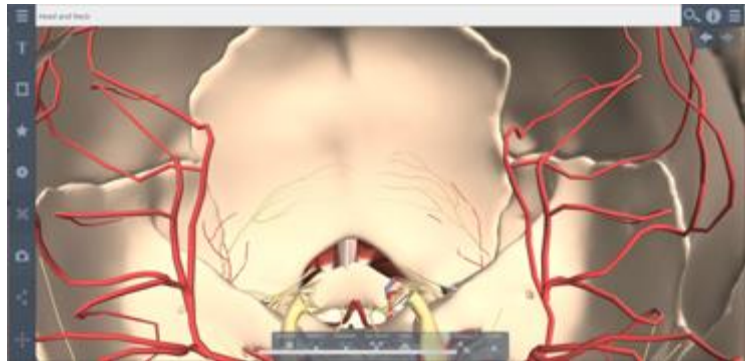■ 点选某个部位就会该部位的相关解释说明：

■ 各种透视化功能，观察该结构后的组织



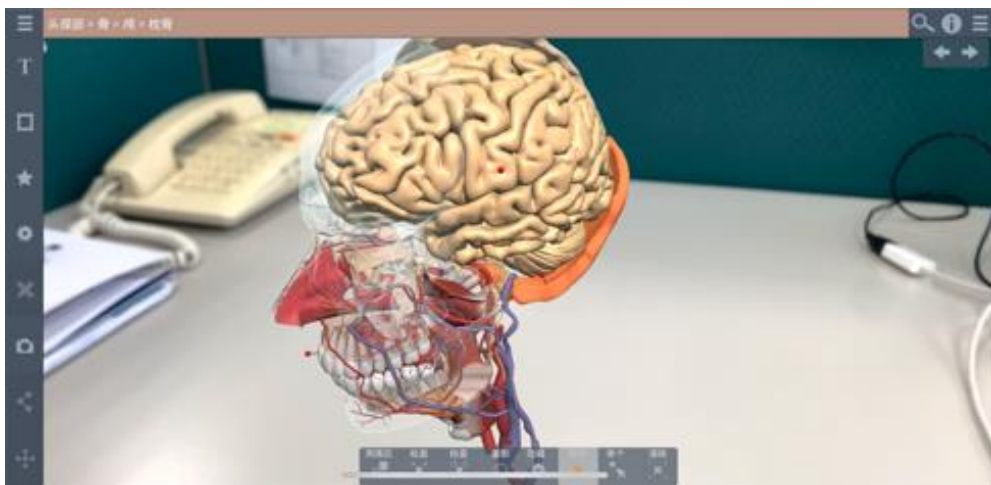
3D Real-Time模块 — 行动App（操作方式都与电脑版相同哦）

- 将手机或平板靠近（或远离）人体组织，层层递进，形成透视效果：

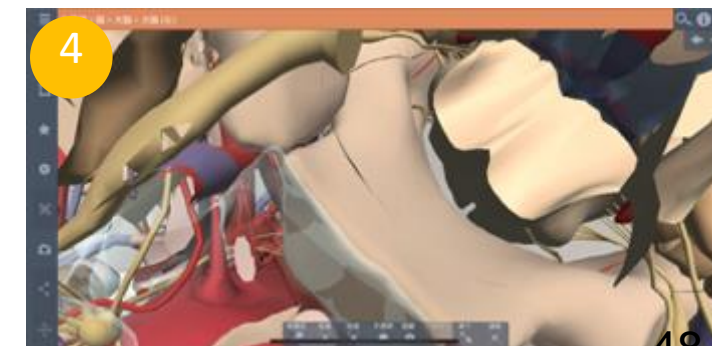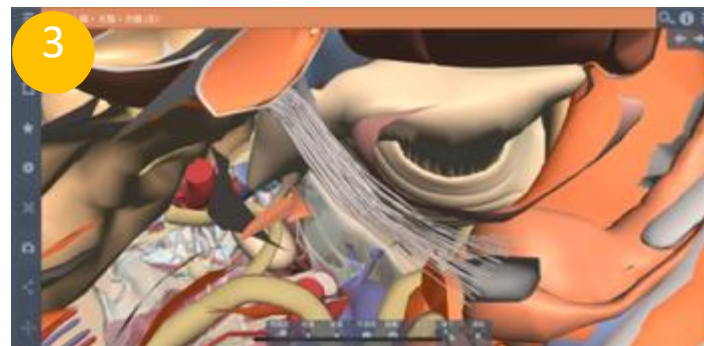
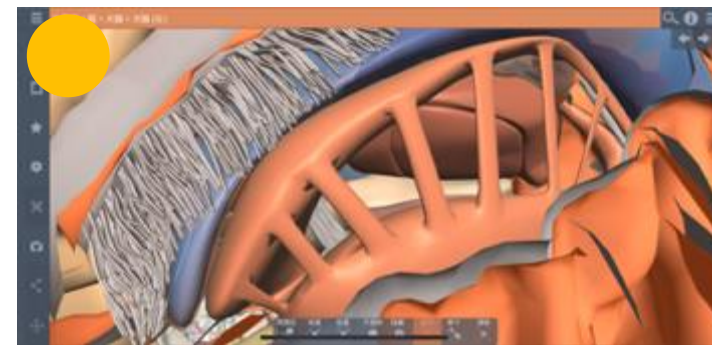

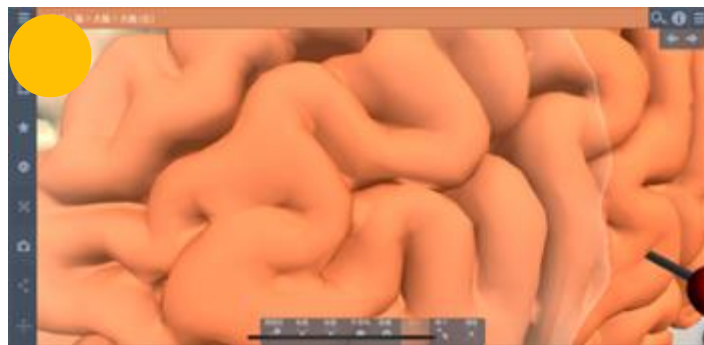
• 范例介绍：

制作好自己的任何模组之后打开AR模式，即可投出画面。



将手机慢慢靠近，进入组织结构，即可层层解剖观看：



Functional Anatomy & Therapy 模块使用界面 – Funtional Anantomy 左方功能栏

The image displays the left sidebar of the Functional Anatomy & Therapy software interface. The sidebar is organized into six main functional categories, each with a corresponding icon and a list of sub-items. The categories are: 3D Views, Slides, Movies, Animations, Anatomical Structures, and Index. Each category is highlighted with a red box. The 3D Views category includes Full body, Upper body, and Lower body. The Slides category includes Dissection slides and Trigger points. The Movies category includes Surface anatomy and Muscle function PowerPoint. The Animations category includes Head and neck, Lower extremity, Pelvic floor, Trunk, Upper extremity, and Gross motor movement. The Anatomical Structures category includes Alimentary system, Esophagus, Large intestine, Small intestine, Stomach, Teeth, Cardiovascular system, Connective tissue, Hepatic system, Lymphatic system, Muscular system, Nervous system, Reproductive system, and Respiratory system. The Index category includes a list of filters and results.

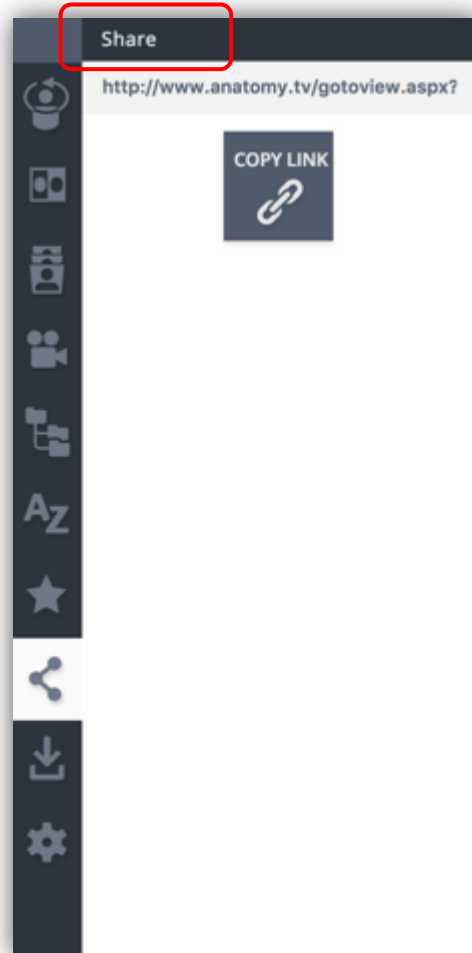
FUNCTIONAL ANATOMY	FUNCTIONAL ANATOMY	FUNCTIONAL ANATOMY	FUNCTIONAL ANATOMY	FUNCTIONAL ANATOMY	FUNCTIONAL ANATOMY
3D Views	Slides	Movies	Animations	Anatomical Structures	Index
<ul style="list-style-type: none"> Full body Upper body Lower body Head and neck Trunk and pelvis Upper limb Lower limb Surface anatomy Trigger points Synovial joints 	<ul style="list-style-type: none"> Dissection slides Trigger points 	<ul style="list-style-type: none"> Surface anatomy Muscle function PowerPoint 	<ul style="list-style-type: none"> Head and neck Lower extremity Pelvic floor Trunk Upper extremity Gross motor movement 	<ul style="list-style-type: none"> Alimentary system Esophagus Large intestine Small intestine Stomach Teeth Cardiovascular system Connective tissue Hepatic system Lymphatic system Muscular system Nervous system Reproductive system Respiratory system 	<p>FILTERS</p> <ul style="list-style-type: none"> 3D Views ✓ Slides ✓ Movies ✓ Animations ✓ Anatomical structures ✓ <p>RESULTS</p> <ul style="list-style-type: none"> 1 2 3 4 5 6 7 8 9 A

Functional Anatomy & Therapy 模块使用界面 – Functional Anatomy 左方控制区

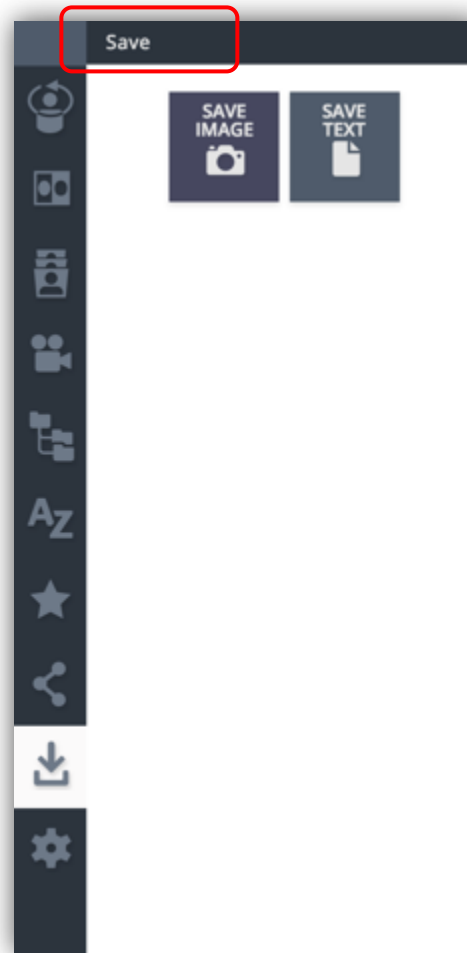我的最爱



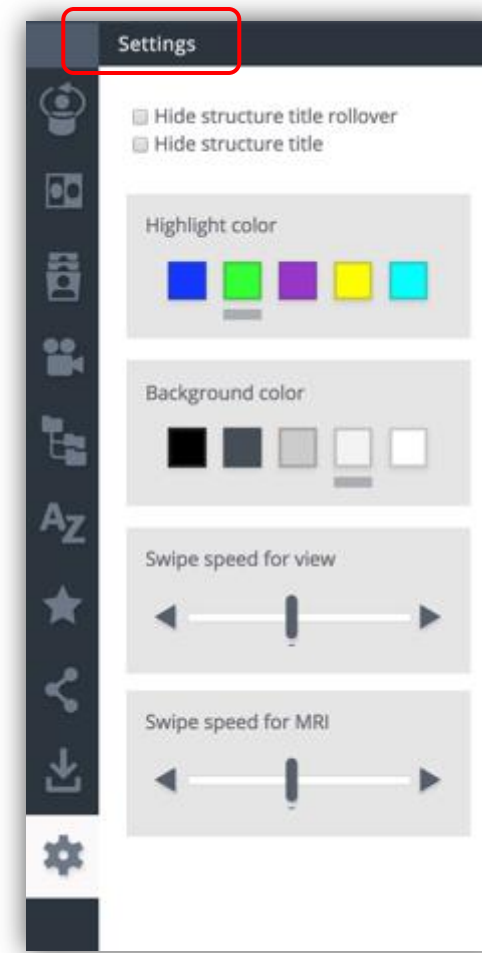
分享链接



保存图片



设定highlight、背景颜色等



Functional Anatomy & Therapy 模块使用界面 – Funtional Anantomy 左方功能栏

FUNCTIONAL ANATOMY
🔍

3D Views

Full body

Upper body

Lower body

Head and neck

Head and neck

Trunk and pelvis

Upper limb

Lower limb

Surface anatomy

Trigger points

Synovial joints

Full body

动脉

神经

静脉
/ 淋巴

Esophagus

The **esophagus** is a continuation of the pharynx at the level of C6. It is about 25 cm in length and empties into the stomach inferiorly. It descends anterior to the vertebral column and posterior to the trachea, passing posterior to the aortic arch and along the right of the descending aorta. It passes through the diaphragm at the level of T10 to end in the cardiac orifice of the stomach. The **lower esophageal sphincter** of the diaphragm constricts the esophagus during respiration to prevent stomach contents from regurgitating.

Blood supply
 Descending aorta.
 Left gastric artery.
 Inferior phrenic artery.

Innervation
 Vagus nerve.
 Thoracic sympathetic trunks.
 Esophageal plexus.
 Lesser splanchnic nerves.
 Greater splanchnic nerves.

CLINICAL RELEVANCE

Disorders of the esophagus often produce chest pain

Visible structures

8

2

不同层次

不同角度

放大缩小 上下颠倒

Functional Anatomy & Therapy 模块使用界面 – Functional Anatomy 左方功能栏

The screenshot displays the 'FUNCTIONAL ANATOMY' software interface. On the left is a vertical sidebar with various icons and a list of anatomical regions: 'Full body', 'Upper body', 'Lower body', 'Head and neck', 'Trunk and pelvis', 'Upper limb', 'Lower limb', 'Surface anatomy', 'Trigger points', and 'Synovial joints'. The 'Full body' option is currently selected. The main area shows a 3D model of a human figure with red muscles and white skin. To the right of the model are navigation arrows and a search bar. Below the model, there is a section titled 'Help and About' with the heading '3D HUMAN FUNCTIONAL ANATOMY'. Underneath, it says 'To help you transition to the new interface:' followed by four cards: 'Transition guide' (with a sub-heading 'Quickly orient yourself to the new interface'), 'Benefits' (with a sub-heading 'Discover how the changes can benefit you'), 'Point-and-click' (with a sub-heading 'For more detailed help:'), and 'User guide'. A Chinese text annotation '可以点击查看指南和资料' (You can click to view guides and materials) has two arrows pointing to the 'Transition guide' and 'Point-and-click' cards.

可以点击查看指南和资料

Functional Anatomy & Therapy 模块使用界面 – Therapy 左方功能栏

PRIMAL'S 3D ATLAS OF MASSAGE AND MANUAL THERAPIES

Movies Lymph drainage: open

Manual therapy techniques

- Craniosacral therapy
 - Craniosacral therapy: technique
- Kinesiotaping
 - Kinesiotaping: preparation
 - Kinesiotaping: application
- Lymph drainage therapy
 - Lymph drainage: open**
 - Lymph drainage: drain
- Massage for the elderly
- Muscle energy techniques

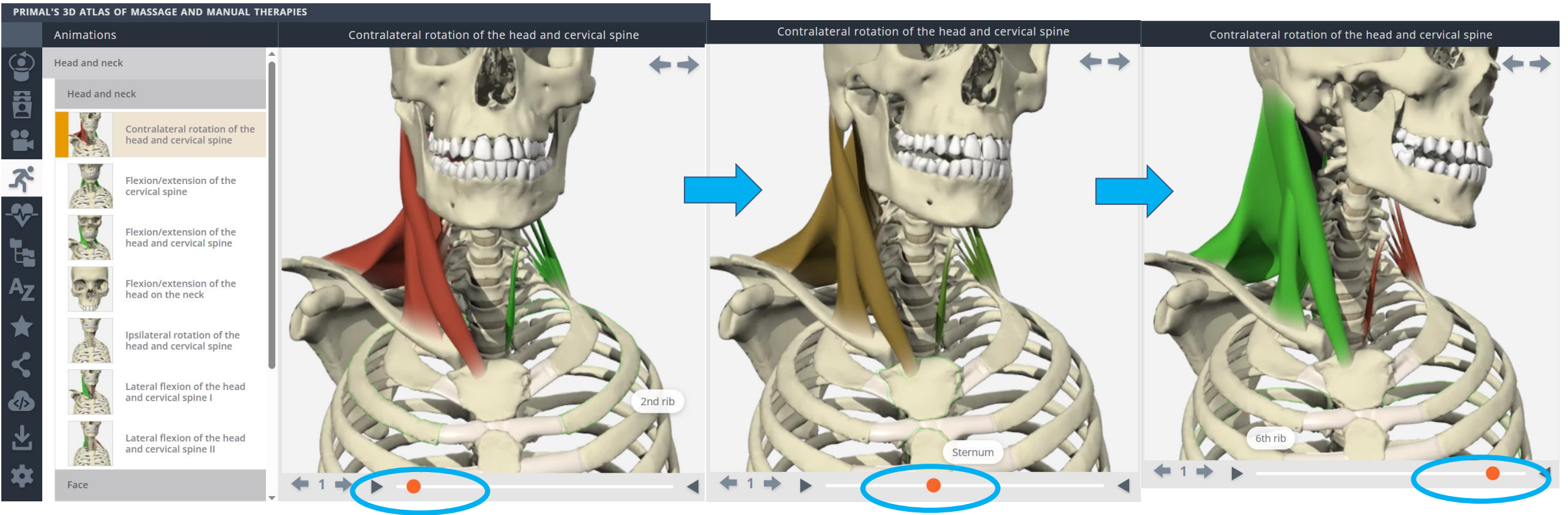
提供多种视频影片



0:00 / 0:22

The image shows a software interface for a manual therapy atlas. On the left is a vertical sidebar with icons and a list of therapy categories. The 'Lymph drainage: open' video is selected and highlighted in yellow. The main area displays a video player with a red text overlay '提供多种视频影片' (Providing various video films) and a video player interface showing a close-up of hands performing a lymph drainage technique on a person's arm. The video player includes a play button, a progress bar at 0:00 / 0:22, and a full-screen button.

Functional Anatomy & Therapy 模块使用界面 – Therapy 左方功能栏



Animations 动画：可以观察肌肉/骨骼在运动过程中的变化

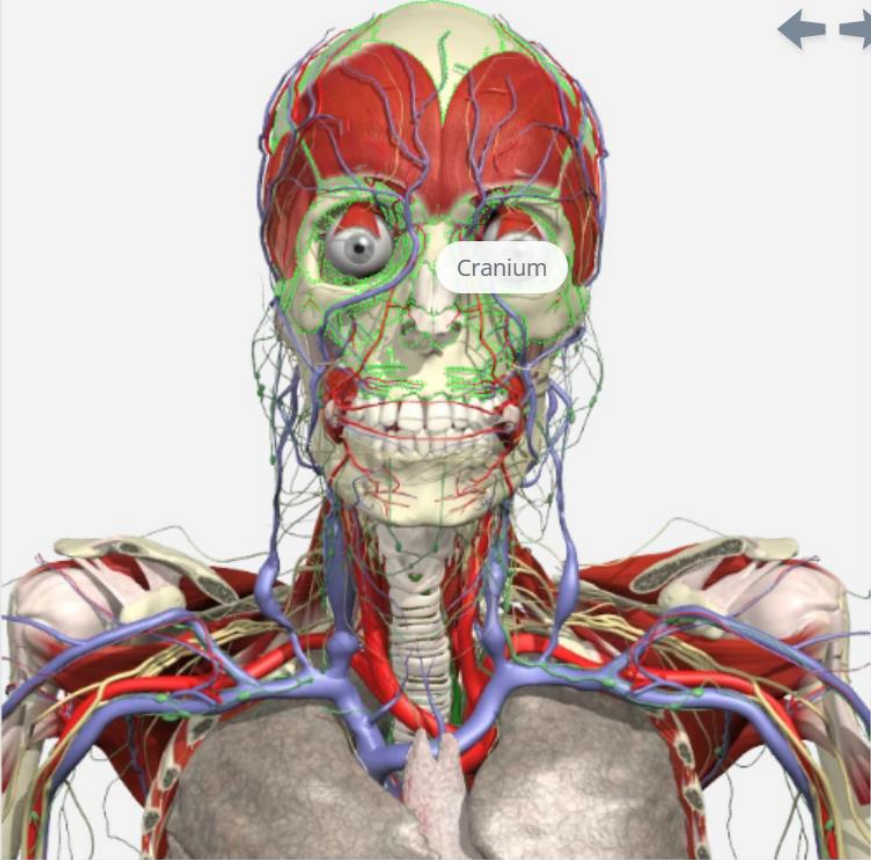
Functional Anatomy & Therapy 模块使用界面 – Therapy 左方功能栏

PRIMAL'S 3D ATLAS OF MASSAGE AND MANUAL THERAPIES

Anatomical Structures

Head and neck

Esophagus



Alimentary system

- Esophagus
- Large intestine
- Small intestine
- Stomach
- Teeth

Cardiovascular system

Connective tissue

Female reproductive system

Hepatic system

Lymphatic system

Male reproductive system

Muscular system

36

Esophagus

The **esophagus** is a continuation of the pharynx at the level of C6. It is about 25 cm in length and empties into the stomach inferiorly. It descends anterior to the vertebral column and posterior to the trachea, passing posterior to the aortic arch and along the right of the descending aorta. It passes through the diaphragm at the level of T10 to end in the cardia, orifice of the stomach. The **lower esophageal sphincter** of the diaphragm constricts the esophagus during respiration to prevent stomach contents from regurgitating.

Blood supply

- Descending aorta.
- Left gastric artery.
- Inferior phrenic artery.

Innervation

- Vagus nerve.
- Thoracic sympathetic trunks.
- Esophageal plexus.
- Lesser splanchnic nerves.
- Greater splanchnic nerves.

CLINICAL RELEVANCE

Disorders of the esophagus often produce chest pain.

Visible structures

有文字说明

Anatomy & Physiology 模块使用界面 – 左方功能栏

HUMAN PHYSIOLOGY AND ANATOMY - BODY PLAN AND ORGANIZATION

Topics

- Introduction
- Structural Organization
- Body Systems
- Principles of Homeostasis
- Anatomical Language

Body systems

Introduction

Learning objectives

BODY PLAN AND ORGANIZATION

INTRODUCTION

A body plan is akin to a blueprint for an organism. It describes the key morphological aspects of that organism and also how it functions as a whole. The human body plan consists of several layers of structural organization culminating in whole body systems, e.g. the cardiovascular and the respiratory systems.

All living things, including the human being, can be distinguished from non-living things via the following basic life processes. There are seven characteristics, listed below, which enable an organism to support and maintain life. Absence or cessation of these processes will result in death of the organism.

Characteristics of life/basic life processes

Metabolism	Biochemical reactions that occur within the body, divided
------------	---

Visible structures

Anatomy & Physiology 模块使用界面 – 左方功能栏

HUMAN PHYSIOLOGY AND ANATOMY - BODY PLAN AND ORGANIZATION

Topics

Body systems

Introduction

Learning objectives

On completing this module, you should be able to:

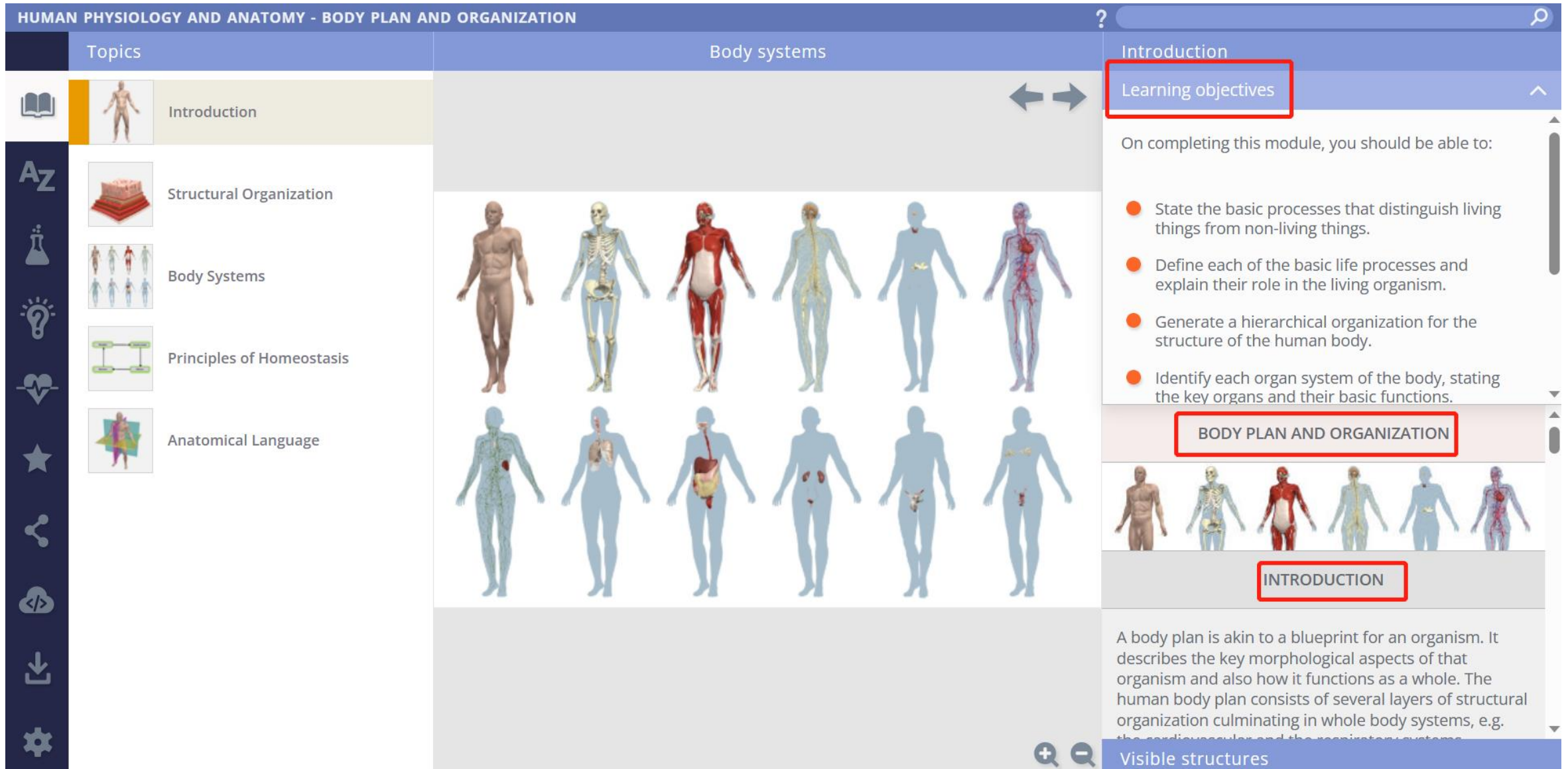
- State the basic processes that distinguish living things from non-living things.
- Define each of the basic life processes and explain their role in the living organism.
- Generate a hierarchical organization for the structure of the human body.
- Identify each organ system of the body, stating the key organs and their basic functions.

BODY PLAN AND ORGANIZATION

INTRODUCTION

A body plan is akin to a blueprint for an organism. It describes the key morphological aspects of that organism and also how it functions as a whole. The human body plan consists of several layers of structural organization culminating in whole body systems, e.g. the cardiovascular and the respiratory systems.

Visible structures



The screenshot displays the user interface for the 'HUMAN PHYSIOLOGY AND ANATOMY - BODY PLAN AND ORGANIZATION' module. On the left, a vertical sidebar contains navigation icons: a book, 'AZ', a flask, a lightbulb, a heart, a star, a share icon, a code icon, a download icon, and a gear. The main content area is divided into two sections: 'Body systems' at the top, featuring a row of six human figures with different systems highlighted (muscular, skeletal, circulatory, nervous, respiratory, and digestive), and a lower section with another row of six figures showing internal organs. The right sidebar is titled 'Introduction' and contains a 'Learning objectives' section with four bullet points. Below this is a table of contents with 'BODY PLAN AND ORGANIZATION' and 'INTRODUCTION' highlighted in red boxes. At the bottom right, there are zoom in (+) and zoom out (-) icons, and a 'Visible structures' label.

Anatomy & Physiology 模块使用界面 – 左方功能栏

HUMAN PHYSIOLOGY AND ANATOMY - BODY PLAN AND ORGANIZATION

Topics

- Introduction
- Structural Organization**
- Body Systems
- Principles of Homeostasis
- Anatomical Language

Levels of structural organization

Structural Organization

Learning objectives

STRUCTURAL ORGANIZATION

Describing the anatomy and physiology of the human body according to the different hierarchical levels of its structural organization can greatly assist in explaining its functions.

The five levels of organization help us to understand the anatomy and physiology of the body:

Chemical > Cellular > Tissue > Organ > System > Organism (the body).

Each subsequent level becomes increasingly complex. However, all levels function through the interaction of their constituent parts. In other words, chemical reactions contribute to cell function, cellular interactions contribute to tissue function, and so on.

Chemical

Chemical > Cellular > Tissue > Organ > System > Organism

The chemical level is the most basic

鼠标往下拉可以看到全部的说明

Anatomy & Physiology 模块使用界面 – 左方功能栏

HUMAN PHYSIOLOGY AND ANATOMY - BODY PLAN AND ORGANIZATION

Interactive Learning 交互学习

Introduction

Az

Body plan and organization

Structural organization

Body systems

Principles of homeostasis

Anatomical language overview

Body plan and organization

Match the following basic life processes with their descriptions.

Life process	Description
<input type="text"/> reproduction	1. increase in body size due to cell development and differentiation
<input type="text"/> differentiation	2. biochemical reactions that occur within the body
<input type="text"/> responsiveness/regulation	3. process by which an unspecialized cell becomes specialized
<input type="text"/> metabolism	4. ability of the body to detect changes in the environment and respond appropriately
<input type="text"/> growth	5. removal of the waste by-products of metabolic reactions
<input type="text"/> excretion	6. formation of new cells in order to repair, replace, or grow new tissue

Question 1 of 5

Anatomy & Physiology 模块使用界面 – 左方功能栏

HUMAN PHYSIOLOGY AND ANATOMY - BODY PLAN AND ORGANIZATION

Quizzes

- Introduction
- Structural Organization
- Body Systems
- Principles of Homeostasis
- Anatomical Language

Body plan and organization

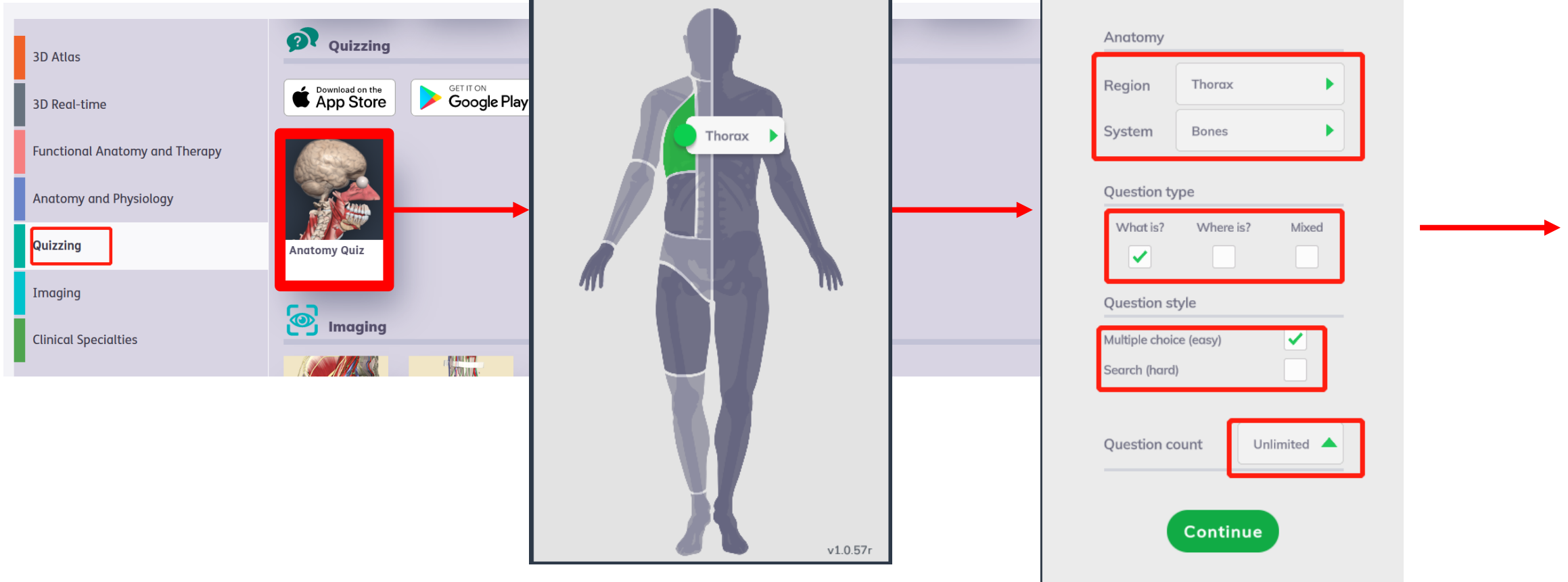
Match the following basic life processes with their descriptions.

Life process	Description
<input type="text"/> metabolism	1. increase in body size due to cell development and differentiation
<input type="text"/> differentiation	2. biochemical reactions that occur within the body
<input type="text"/> excretion	3. process by which an unspecialized cell becomes specialized
<input type="text"/> growth	4. ability of the body to detect changes in the environment and respond appropriately
<input type="text"/> responsiveness/regulation	5. removal of the waste by-products of metabolic reactions
<input type="text"/> reproduction	6. formation of new cells in order to repair, replace, or grow new tissue

Question 1 of 5

自我测试

Quizzing 模块使用界面 – 使用指南



选择想要测试的部位

自由设定测试方式

Quizzing 模块使用界面 – 使用指南

The screenshot displays the Quizzing module interface. At the top, a dark blue header contains the question "What is highlighted?" and a "Hide options" button. Below the question, there are six multiple-choice options, each with an unchecked checkbox:

- Erector spinae (Syn. sacrospinalis): longissimus thoracis
- Lateral thoracic vein
- Humerus
- Seventh thoracic vertebra
- Secondary bronchi
- Sixth thoracic vertebra

The main area of the interface features a 3D anatomical model of the human thorax, with the humerus highlighted in orange. A red arrow points to the left side of the model. On the right side, there is a vertical toolbar with a person icon and a "Pass" button. At the bottom left, there are "CONTROL", "EXAMINE", and "FOCUS" icons. At the bottom right, there is a score indicator showing "0/0".

Below the main interface, a red arrow points to the "Results" screen. The "Results" screen has a dark blue header with the word "Results". It displays the following information:

- "You scored"
- 1 / 1 100 %**
- Thorax | Bones
- Wednesday, 31 May 2023 10:39 AM
- Exit the quiz to revise your anatomy with the 3D model
- Exit quiz (red button) and New quiz (yellow button)
- Earn a medal for runs of correct answers
- GOLD Run of 15 (0 medals)
- SILVER Run of 10 (0 medals)
- BRONZE Run of 5 (0 medals)

Imaging 模块使用界面 – 左方功能栏

The screenshot displays the PRIMAL'S 3D HUMAN ANATOMY FOR ULTRASOUND: LOWER LIMB interface. The left sidebar contains the following navigation options:

- 3D Views
- Ultrasound transducer positions
 - Hip ~ ultrasound transducer positions (highlighted)
 - Knee ~ ultrasound transducer positions
 - Foot ~ ultrasound transducer positions
- Histology
- Lower limb
- Hip
- Hip and thigh
- Knee
- Leg and foot
- Foot and ankle
- Nervous system

The central 3D model shows the hip region with various structures labeled, including "Levator ani". The right sidebar contains help and information sections:

- Help and About
- 3D HUMAN ANATOMY FOR ULTRASOUND: LOWER LIMB
- To help you transition to the new interface:
 - Transition guide
 - Benefits
- For more detailed help:
 - Point-and-click
 - User guide
- Visible structures

At the bottom of the interface, there are navigation controls including a stack icon with the number 1, up and down arrows, a 3D rotation icon, a cube icon with the number 36, and a search icon.

Imaging 模块使用界面 – 左方功能栏

PRIMAL'S 3D HUMAN ANATOMY FOR ULTRASOUND: LOWER LIMB

Imaging

Hip

Axial

US 1 of inguinal ligament

US 1 of femoral vessels and iliopsoas

US 1 of proximal origin of rectus femoris

US 1 of tensor fasciae latae and hip abductors

US 1 of proximal iliotibial tract and muscle bellies of gluteus medius and minimus

EFOV US 1 of gluteal muscles

US 1 of sciatic nerve and gluteus maximus

US 1 of inguinal canal

US 1 of inguinal ligament

Clinical link [Inguinal and femoral hernias; Reactive inguinal lymph nodes](#)

Technique
With the patient lying supine and the transducer held in an axial plane, the inferior epigastric vessels are first identified where they

MRI图和还原图对比

锁上是同时变换层级，解锁是单独各自变换层级

对比图可以同时或单独呈现不同层级

点击橙色部分观看更详细说明

锁上是同时变换层级，解锁是单独各自变换层级

对比图可以同时或单独呈现不同层级

Imaging 模块使用界面 – 左方功能栏

PRIMAL'S 3D HUMAN ANATOMY FOR ULTRASOUND: LOWER LIMB

Slides

Clinical slides

MR images

Hip

Axial

Hip: axial MR image 1

Hip: axial MR image 2

Hip: axial MR image 3

Sagittal

Coronal

Knee

Foot

Ultrasound images

Hip: axial MR image 1

US 1 of inguinal ligament

Clinical link: Inguinal and femoral hernias; Reactive inguinal lymph nodes

Display ultrasound image

Technique

With the patient lying supine and the transducer held in an axial plane, the superficial inguinal vessels are first identified with the probe deep to the rectus abdominis muscle. The superficial vessels are then followed to their origin from the external iliac vessels. The transducer is then rotated into the expected plane of the inguinal ligament running from the pubic tubercle to the anterior superior iliac crest. If the transducer pressure is light, tubular hypo-echoic structures may be seen deep to the echogenic fibrillary structure of the inguinal ligament representing the spermatic cord (in a male) and vessels in the inguinal canal. The inferior epigastric vessels provide a landmark for the superficial inguinal ring, which lies medial to them and the deep ring, which is lateral. The canal may also be examined in short axis by rotating the transducer through 90 degrees into a parasagittal plane. In these two positions, a dynamic examination is performed during the straining phase and, often more usefully, the relaxing phase of a Valsalva maneuver. An inguinal hernia will then be seen as abdominal fat or bowel moving into the inguinal canal and enlarging it on straining. The examination should be repeated

Obturator internus

可以从不同切面观看图片

点击橙色部分进一步
观看资料

Imaging 模块使用界面 – 左方功能栏

PRIMAL'S 3D HUMAN ANATOMY FOR ULTRASOUND: LOWER LIMB

Chronic tear of semitendinosus normal comparison: axial dynamic US

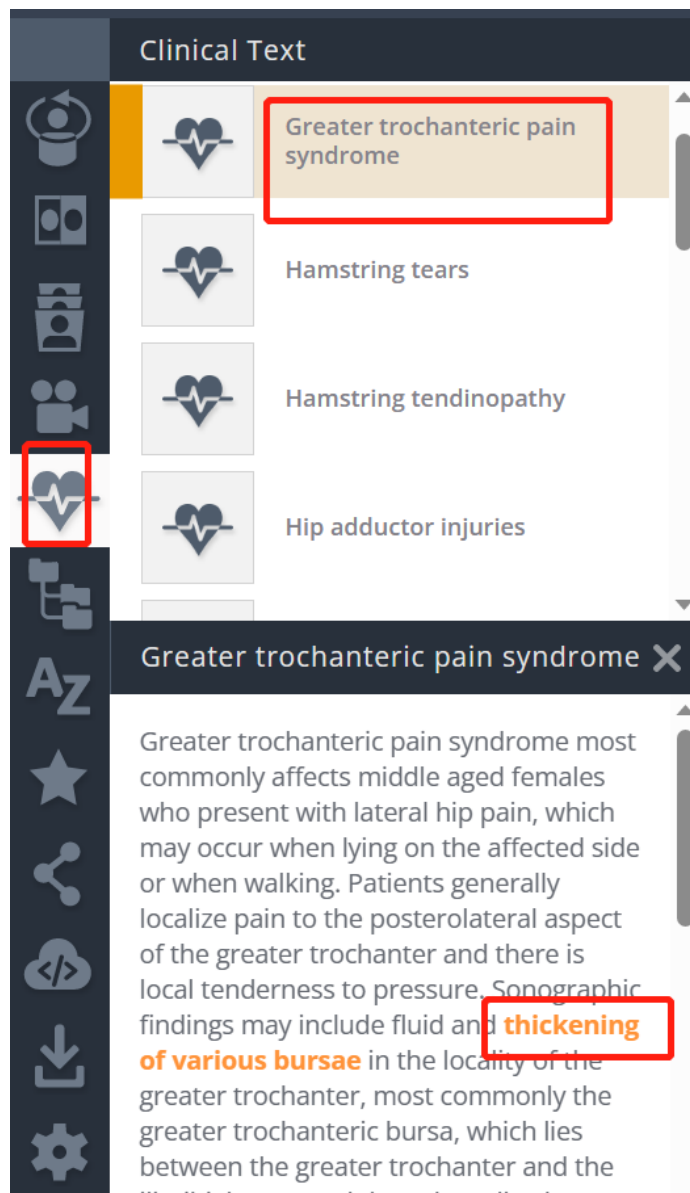
Movies

- Chronic tear of semitendinosus normal comparison: axial dynamic US
- Chronic tear of semitendinosus: axial dynamic US
- Chronic tear of semitendinosus: longitudinal dynamic US
- Inguinal hernia: axial oblique dynamic US
- Inguinal hernia: parasagittal dynamic US

视频

0:13 / 0:13

Imaging 模块使用界面 – 左方功能栏



临床文本

Imaging 模块使用界面 – 左方功能栏

PRIMAL'S 3D HUMAN ANATOMY FOR ULTRASOUND: LOWER LIMB

Anatomical Structures

Vessels of hip and thigh

Abdominal aorta

Arteries

Arteries of abdomen

Abdominal aorta

Common iliac artery

External iliac artery

Iliolumbar artery

Lumbar arteries

Arteries of lower limb

Arteries of pelvis

Blood vessel micro-anatomy

Attachments

Origin

The continuation of the *descending thoracic aorta* as it passes through the diaphragmatic aortic aperture.

Course

It descends over the lumbar vertebrae and associated anterior longitudinal ligament and terminates at the level of L4 by dividing into the *common iliac arteries*.

Branches

Celiac trunk.
Inferior mesenteric artery.
Inferior phrenic arteries.
Lumbar arteries.
Median sacral artery.
Middle suprarenal artery.
Ovarian artery.
Renal artery.
Superior mesenteric artery.
Testicular artery.

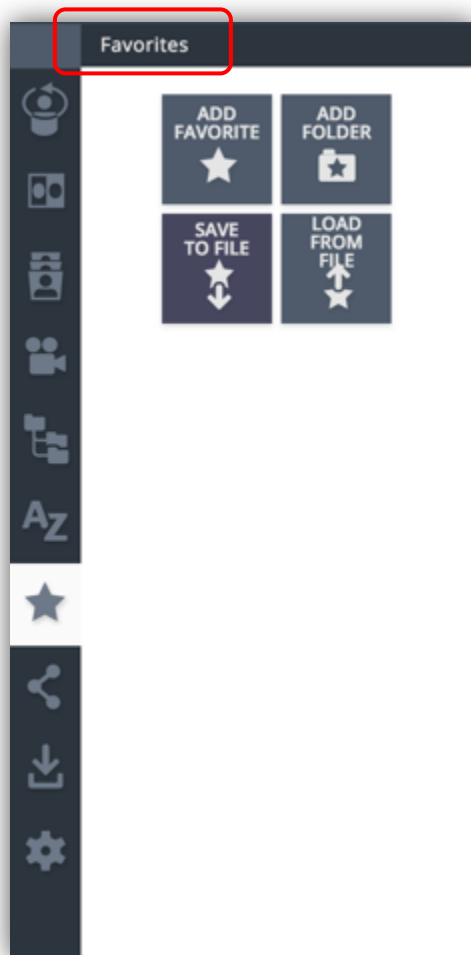
Supply

Through its branches it supplies the:
Abdomen.
Lower limb.

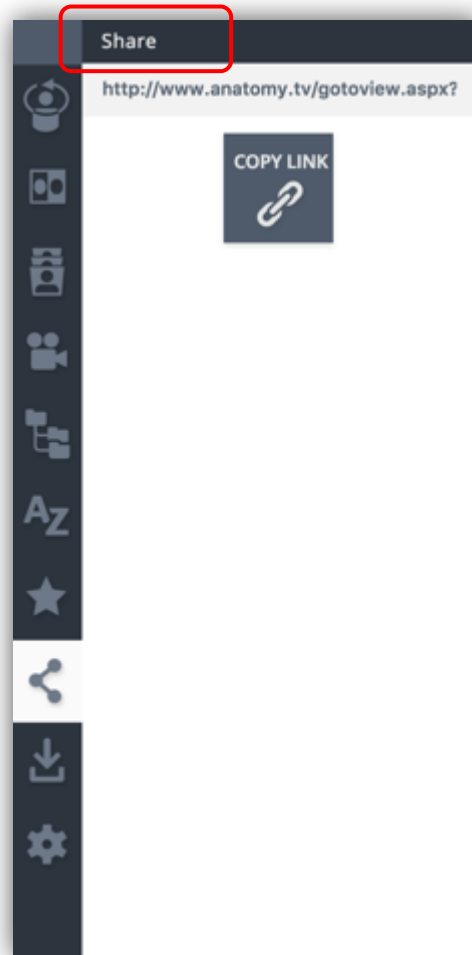
文字说明

Imaging 模块使用界面 – 左方功能栏

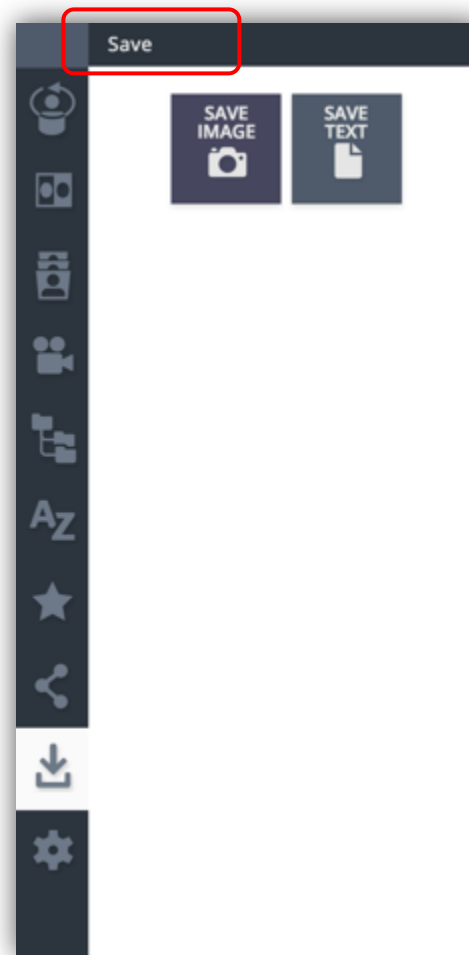
我的最爱



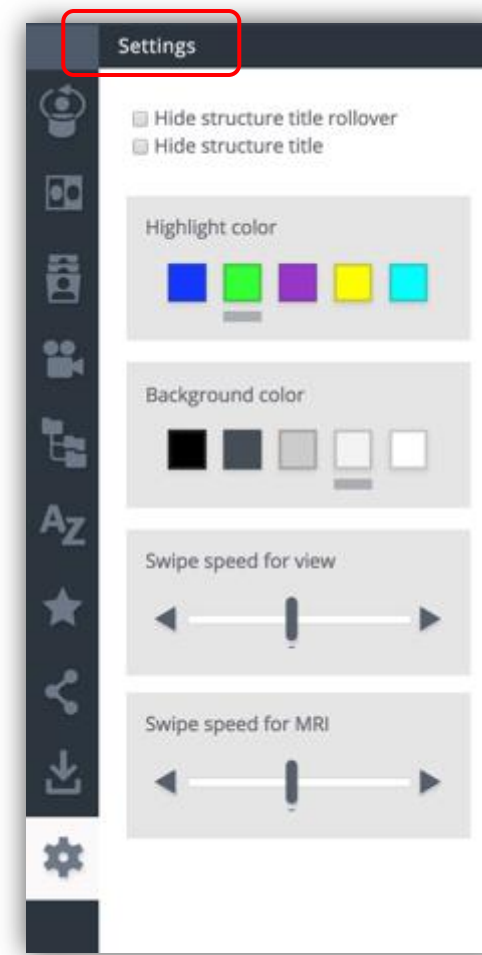
分享链接



保存图片



设定highlight、背景颜色等



Clinical Specialties 模块使用界面

Clinical Specialties

Audiology

Otolaryngology

Dentistry

Dental Hygiene

Real-time Dentistry

Speech Language Pathology

Pelvic Floor Disorders

Head and Neck

Chiropractic

Urology

自行选择模组

以下以牙科为例

Clinical Specialties 模块使用界面 – 左方功能栏

The screenshot displays the 'DENTISTRY' module interface. On the left, a vertical toolbar contains various icons, with a red box highlighting the 3D view icon. Below the toolbar, a list of 3D views is shown, with '3D Views' highlighted in a red box. The selected view is 'Dentition and paranasal sinuses ~ overview', also highlighted in a red box. The central panel shows a 3D anatomical model of the head and neck, with a red box highlighting the '3D' label and a 'Teeth: molars' tooltip. The right panel contains a 'Help and About' section with a red box highlighting the 'Transition guide' link, and a red text annotation '右方有进一步资料' (Further information on the right) pointing to the help content. The bottom of the interface shows a 'Visible structures' list with a red box highlighting the '8' icon.

DENTISTRY

3D Views

Head and neck

Head (close)

Neck (close)

Anterior neck

Oronasal cavities

Oral cavity

Dentition and clinical relevance

Dentition and paranasal sinuses ~ overview

Numbering systems ~ adult dentition

Dentition and paranasal sinuses ~ over...

Teeth: molars

3D

Help and About

3D HEAD AND NECK ANATOMY FOR DENTISTRY

To help you transition to the new interface

Transition guide

Benefits

Quickly orient yourself to the new interface

Discover how the changes can benefit you

For more detailed help:

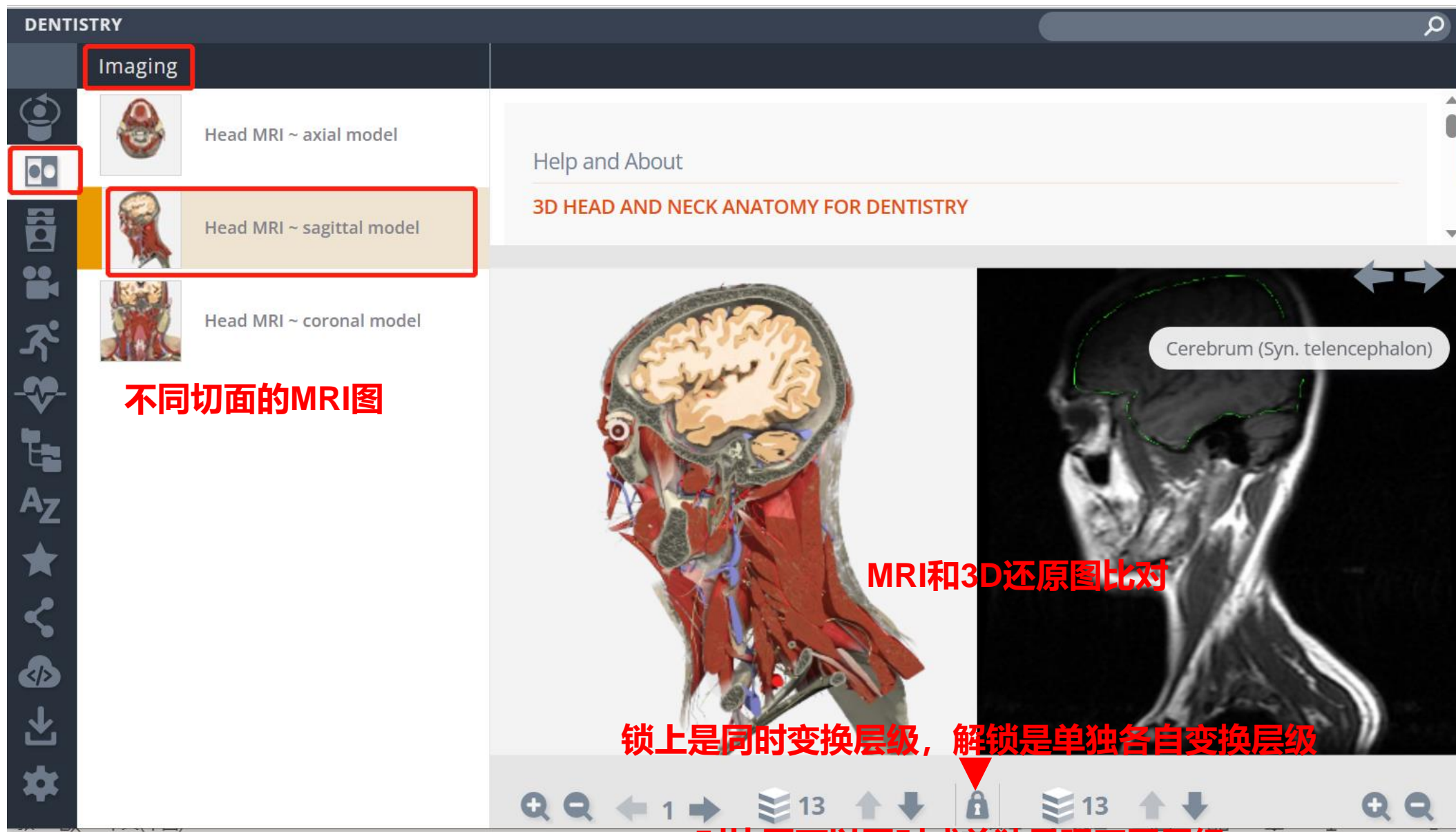
Point-and-click

User guide

Visible structures

右方有进一步资料

Clinical Specialties 模块使用界面 – 左方功能栏



不同切面的MRI图

MRI和3D还原图比对

锁上是同时变换层级，解锁是单独各自变换层级

对比图可以同时或单独呈现不同层级

Clinical Specialties 模块使用界面 – 左方功能栏

The screenshot displays the 'DENTISTRY' module interface. On the left is a vertical sidebar with various icons. The 'Slides' menu is highlighted with a red box, and the 'Action of the inferior rectus muscles' slide is selected. The main content area shows a diagram of the eye with labels for 'SUPERIOR', 'INFERIOR', 'LATERAL', and 'MEDIAL'. Red arrows indicate the muscle's actions: 'Elevation' (upward), 'Depression' (downward), and 'Lateral rectus muscle' (outward). The text '投影片说明' (Slide description) is overlaid in red. The right sidebar contains 'Help and About' and '3D HEAD AND NECK ANATOMY FOR DENTISTRY' sections, including a 'Transition guide' and 'Benefits' section.

DENTISTRY

Slides

Anatomy illustrations

- Action of the cricothyroid muscle
- Action of the inferior oblique muscles
- Action of the inferior rectus muscles**
- Action of the medial and lateral rectus muscles
- Action of the superior oblique muscles
- Action of the superior rectus muscles
- Actions of lateral cricoarytenoid and thyroarytenoid muscles

投影片说明

Action of the inferior rectus muscles

Help and About

3D HEAD AND NECK ANATOMY FOR DENTISTRY

To help you transition to the new interface:

- Transition guide**
Quickly orient yourself to the new interface
- Benefits**
Discover how the changes can benefit you

For more detailed help:

- Point-and-click**
- User guide**

Clinical Specialties 模块使用界面 – 左方功能栏

DENTISTRY

Movies

Biomechanics animations

Close view of the depression and elevation of the temporomandibular joint

Inferior view of the depression and elevation of the temporomandibular joint

Inferior view of the lateral movement of the temporomandibular joint

Inferior view of the protrusion and retraction of the temporomandibular joint

Lateral view of the depression and elevation of the temporomandibular joint

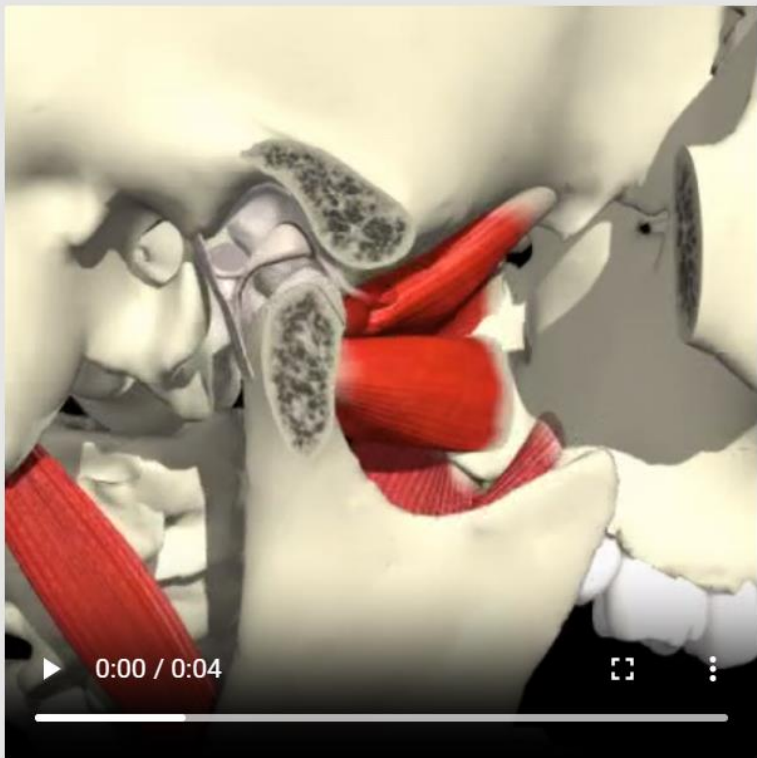
Lateral view of the lateral movement of the temporomandibular joint

Lateral view of the protrusion and retraction of the temporomandibular joint

Medial view of the depression

Close view of the depression and elevation of the temporomandibular joint

视频



0:00 / 0:04

The image shows a software interface for dental education. On the left is a vertical sidebar with various icons, including a video camera icon that is highlighted with a red box. The main area on the right displays a video player with a 3D anatomical model of the temporomandibular joint. The video title is 'Close view of the depression and elevation of the temporomandibular joint'. A red Chinese character '视频' (Video) is overlaid on the left side of the video player. The video player shows a close-up of the joint with red muscles and white bones. The video progress bar indicates 0:00 / 0:04. There are also navigation arrows and a search icon at the top right of the interface.

Clinical Specialties 模块使用界面 – 左方功能栏

The screenshot displays the 'DENTISTRY' module interface. The main window shows a 3D anatomical model of a human skull and neck in a sagittal view, with the text 'Elevation/depression of the corners of the mouth' at the top. A red Chinese character '动画' (Animation) is overlaid on the skull. A callout box points to the 'First cervical vertebra (Syn. atlas)'. The left sidebar contains a menu with 'Animations' highlighted in red. The menu items include: cervical spine, Flexion/extension of the head and cervical spine, Flexion/extension of the head on the neck, Ipsilateral rotation of the head and cervical spine, Lateral flexion of the head and cervical spine I, Lateral flexion of the head and cervical spine II, Movements of the eye, Movements of the face, Elevation/depression of the corners of the mouth (highlighted in red), and Elevation/depression of the eyebrows. The right sidebar contains 'Help and About' and '3D HEAD AND NECK ANATOMY FOR DENTISTRY'. Below this, it says 'To help you transition to the new interface:' and provides links for 'Transition guide' and 'Benefits'. Further down, it says 'For more detailed help:' and provides links for 'Point-and-click' and 'User guide'. At the bottom right, there is a 'Visible structures' section.

DENTISTRY

Animations

cervical spine

Flexion/extension of the head and cervical spine

Flexion/extension of the head on the neck

Ipsilateral rotation of the head and cervical spine

Lateral flexion of the head and cervical spine I

Lateral flexion of the head and cervical spine II

Movements of the eye

Movements of the face

Elevation/depression of the corners of the mouth

Elevation/depression of the eyebrows

Elevation/depression of the corners of the mouth

动画

First cervical vertebra (Syn. atlas)

Help and About

3D HEAD AND NECK ANATOMY FOR DENTISTRY

To help you transition to the new interface:

Transition guide

Benefits

Quickly orient yourself to the new interface

Discover how the changes can benefit you

For more detailed help:

Point-and-click

User guide

Visible structures

Clinical Specialties 模块使用界面 – 左方功能栏

DENTISTRY

Dentistry

Embryogenesis

Pharyngeal pouches, clefts and arches

Thyroid

Development of thyroid

Examination of thyroid

Developmental anomalies of thyroid

Development of thyroid

During weeks 3-4 a median endodermal thyroid diverticulum appears opposite the first and second pharyngeal pouches (Slide 1, Slide 2, Slide 3). It forms a bi-lobed structure which then descends down through the neck leaving the foramen cecum as the original site mark. During the first trimester of pregnancy the thyroid gland is located in the lower neck. It descends to the laryngeal cartilages. By week 7 it has reached its site in the neck. The caudal pharyngeal complex is thought to give rise to the 'C' cells of the thyroid. They store and secrete calcitonin. They are of

Diagram of structures derived from brachial (pharyngeal) pouches

PHARYNGEAL POUCHES

Dorsal

Auditory (Eustation) tube

I

II

III

IV

Inf

Sup

Parathyroid

Diverticulum

Ventral

Tongue

Tonsils

Thyroid

Thymus

Caudal Pharyngeal Complex (Calcitonin cells)

Help and About

3D HEAD AND NECK ANATOMY FOR DENTISTRY

To help you transition to the new interface:

Transition guide

Benefits

Quickly orient yourself to the new interface

Discover how the changes can benefit you

For more detailed help:

Point-and-click

User guide

Use our interactive

A downloadable PDF

点击橙色部分

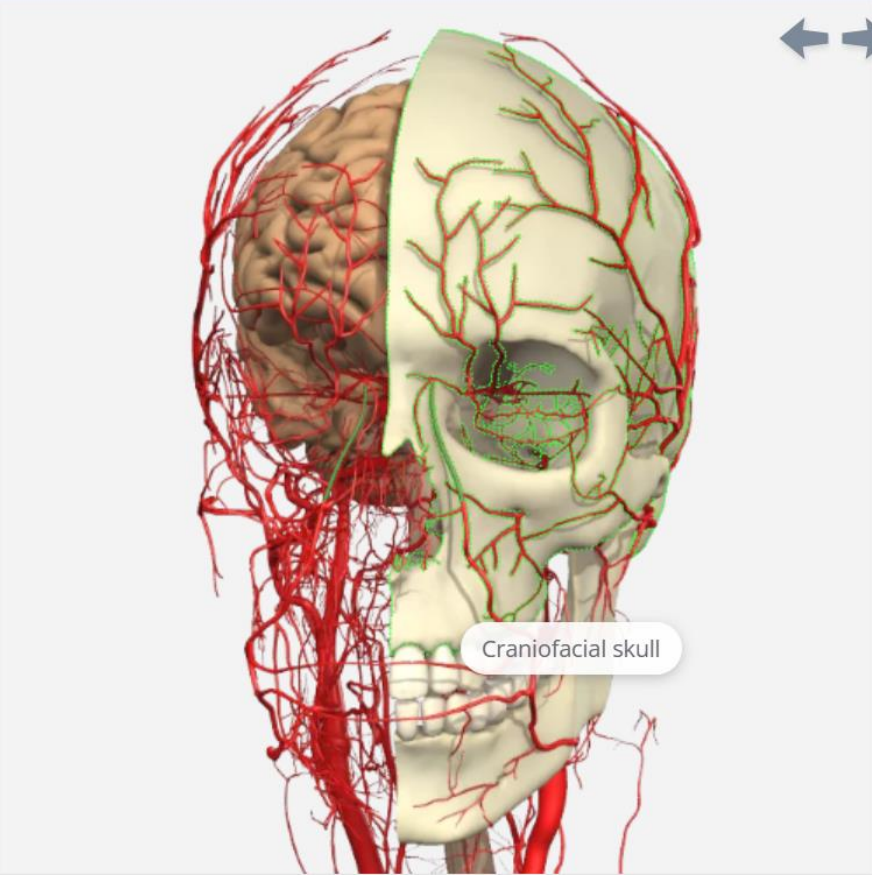
Clinical Specialties 模块使用界面 – 左方功能栏

DENTISTRY

Anatomical Structures

- Occlusal surface
- Arteries
 - Accessory meningeal artery
 - Angular artery**
 - Anterior cerebral artery
 - Anterior cerebral artery: frontal branches
 - Anterior cerebral artery: orbital branches
 - Anterior cerebral artery: parietal branches
 - Anterior choroidal artery

Head (close)



Angular artery

Origin
The terminal part of the external maxillary artery is the angular artery.

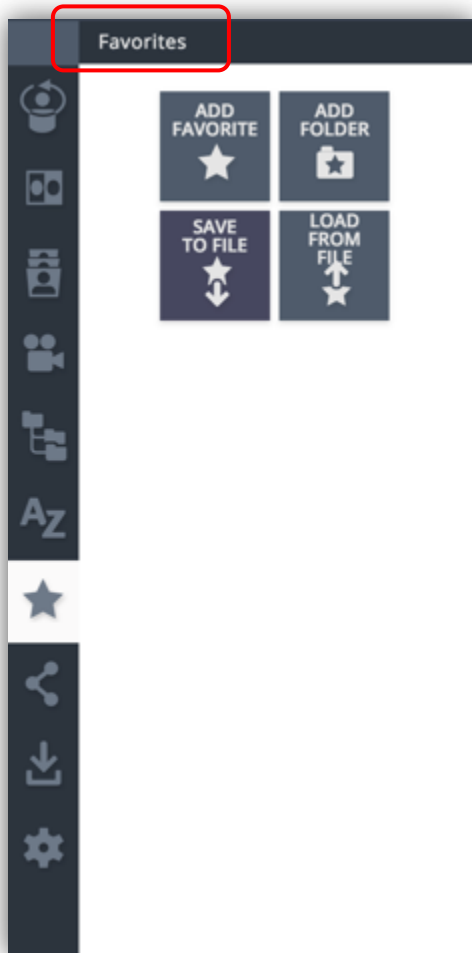Course
It ascends up to the medial angle of the orbit. It travels through the substance of the angular head of the orbicularis oris muscle, the labii superioris quadrant; the angular vein accompanies it. It terminates in the cheek by anastomosing with the dorsal nasal branch of the ophthalmic artery.

Supplies
After supplying the lacrimal sac and orbicularis oculi muscle, the angular artery distributes branches that anastomose with the infra-orbital.

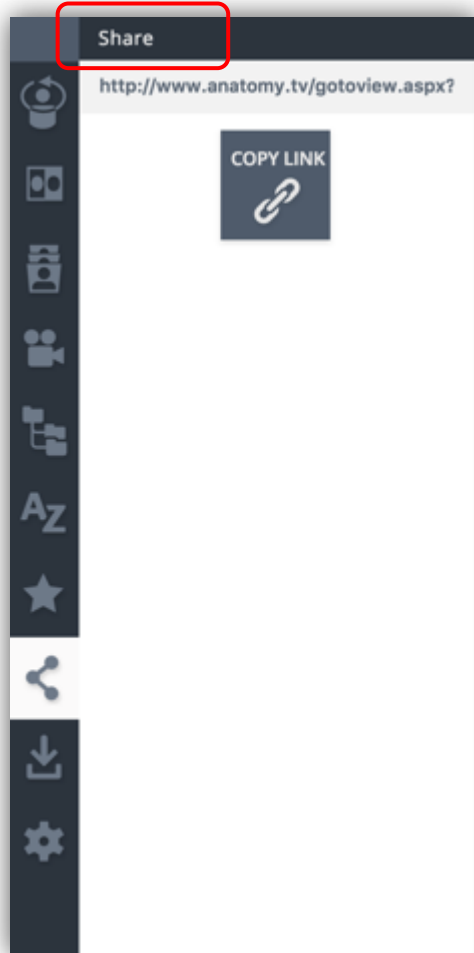
Visible structures

Clinical Specialties 模块使用界面 – 左方功能栏

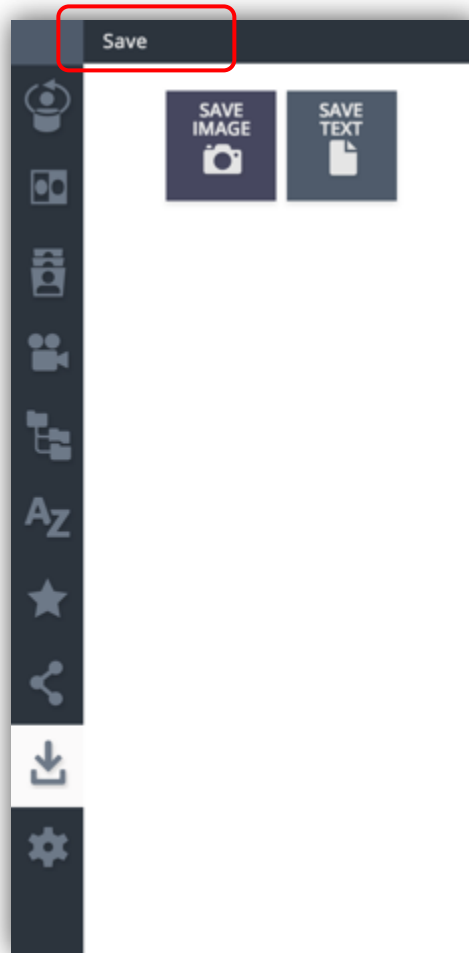我的最爱



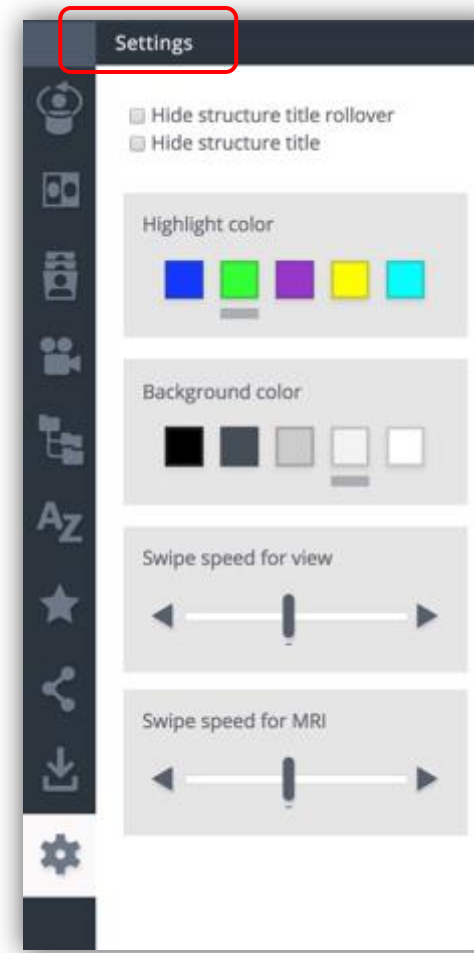
分享链接



保存图片



设定highlight、背景颜色等





PRIMAL PICTURES

微信公众号

